



Identification and Removal of Lingual and Palatine Tonsils as SRMs in Beef Market Heads and Tongues

USDA-FSIS-OPPD



FSIS Policy on Beef Tonsils

- n Beef tonsils are identified as “**specified risk materials**” (SRMs) in cattle of **all ages** per **9 CFR 310.22(a)(2)**.
- n FSIS policy has focused on removal of **palatine and lingual tonsils** in beef and is outlined in Chapter II, Part V. of **FSIS Directive 6100.4**.



Beef Market Heads

- n Beef Market Heads are typically sold as “whole” beef heads with tongue.
- n Beef Market Heads can only be saved from cattle less than 30 months of age after removal of grossly identifiable (i.e. visible to the unaided eye) palatine and lingual tonsil tissue (SRM) within specified landmarks.



Beef Market Heads

- n Whole beef market heads cannot be saved from cattle 30 months and older as the entire skull and associated non-meat components are considered SRM material per 9 CFR 310.22(a)(1).



FSIS Policy on Beef Palatine and Lingual Tonsils

- n *Palatine and lingual tonsil* in the oropharynx are the designated tonsils (SRM) that must be removed during head boning including preparation of beef market heads and tongues. *Other tonsils need not be removed as SRM unless found to be unwholesome.*



FSIS Policy on Beef Pharyngeal and Tubal Tonsils

- n Based on a lack of scientific evidence, the **pharyngeal and tubal tonsils** of the nasopharynx, are not considered SRM and need not be removed unless found to be unwholesome.*



FSIS Verification Procedures for Removal of Tonsils in Beef Market Heads

- § FSIS Inspection personnel should follow verification procedures outlined in FSIS Directive 6100.4 regarding SRM removal procedures in the plant's HACCP, SSOP, or pre-requisite program procedures to remove the designated tonsil tissue (SRM) of concern from beef market heads and tongues.



Why the concern over Beef Market Heads?

1. Nationwide Data Analysis of SRM related NRs and a recent recall suggest not all specified tonsil tissue is being adequately removed from beef market heads and tongues.



Why the concern over Beef Market Heads?

2. Due to differences in processing of beef market heads compared to regular boning of beef heads, the verification of adequate removal of palatine and lingual tonsil from beef market heads requires more in-depth knowledge of head anatomy and location of tonsils.



FSIS Verification Procedures for Beef Tonsils

n From FSIS Directive 6100.4:

1. *Inspection program personnel are to verify that the establishment's procedures for the removal, segregation, and disposition of **tonsils** [using] ... accepted head dressing procedures [that include] removal of [tonsils on] the tongue...*



FSIS Verification Procedures for Beef Tonsils (2)

- n 2. If an establishment harvests tongue for human food, inspection program personnel are to verify that the establishment's harvesting procedure includes making a *transverse cut*, or effectively *skinning* caudal (just behind) to the last *vallate papillae* on the tongue, to ensure complete removal of *lingual tonsils*.



Objectives

- n Review the basic anatomy of the beef head observed during head inspection.
- n Identify location and gross appearances of bovine palatine and lingual tonsils on:
 1. Beef market head
 2. Beef tongues



Approach to Objectives

- n Beef head inspection entails incision of the four (4) sets of lymph nodes and cheek muscles of the head.
- n Occasionally, *tonsils* may be observed during *head inspection*; therefore, we will demonstrate tonsils in a manner familiar to FSIS inspectors.



Approach to Objectives (2)

This presentation will be accessible with other SRM guidance material on the FSIS PDD (Technical Service Center) website at:

[http://www.fsis.usda.gov/Regulations & Policies/Policy_Points/index.asp#SRM](http://www.fsis.usda.gov/Regulations_and_Policies/Policy_Points/index.asp#SRM)



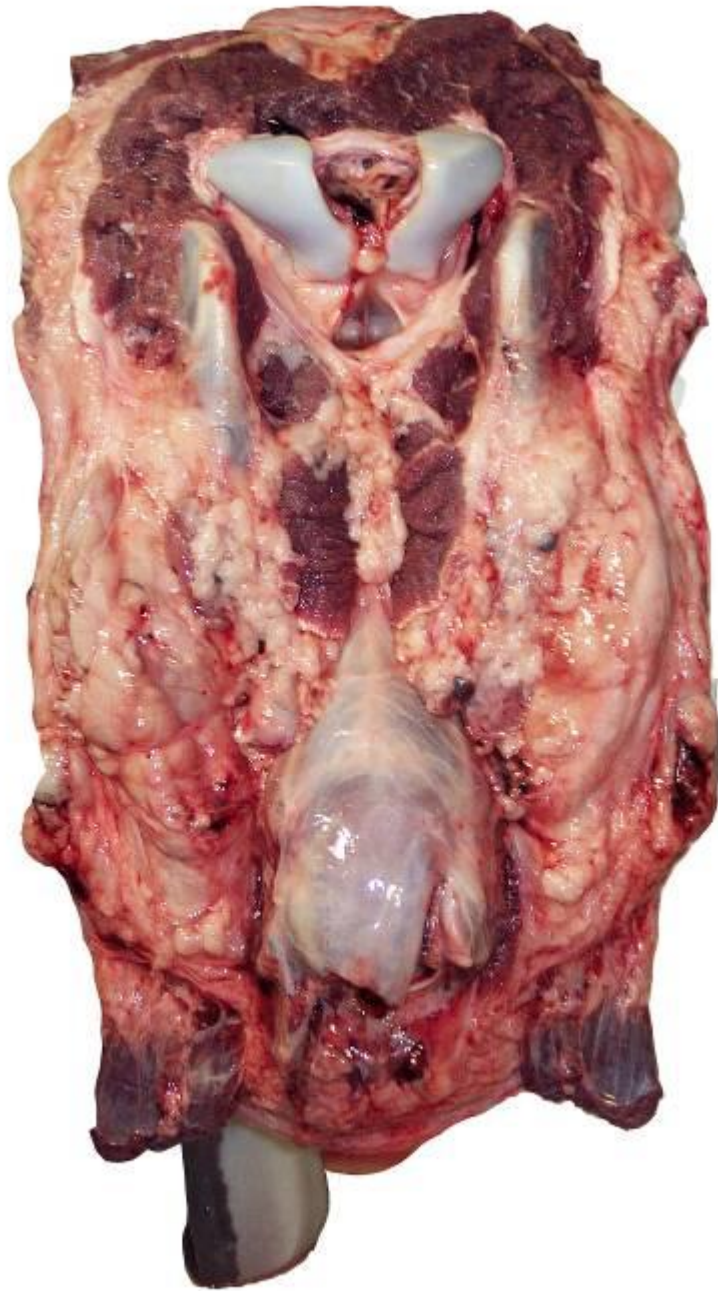Review of Head Inspection Anatomy

- n Before locating and identifying the specified tonsils in a beef market head, it is beneficial to review the *anatomical landmarks* on the beef head observed during head inspection.

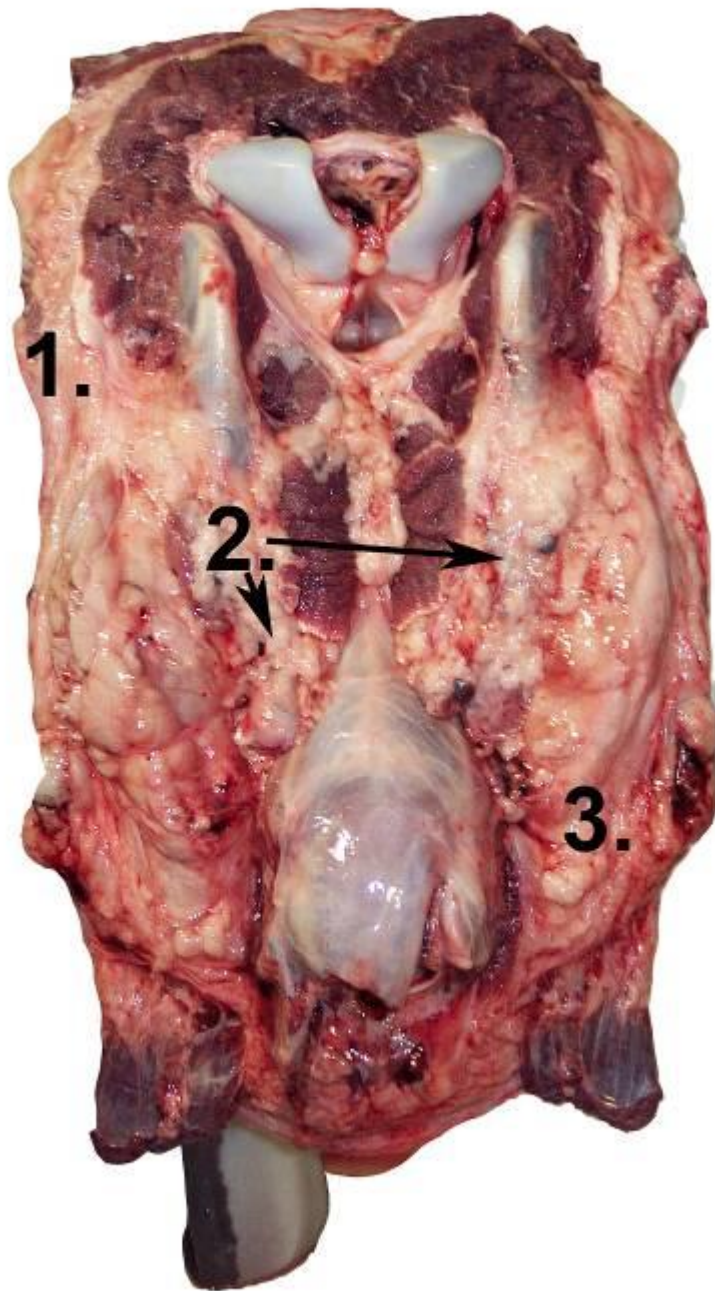


Review of Head Inspection Anatomy (2)

- n This presentation will identify the specified *palatine and lingual tonsils* (SRMs) as they may be exposed while performing head inspection using a *tongue-in head inspection procedure*.



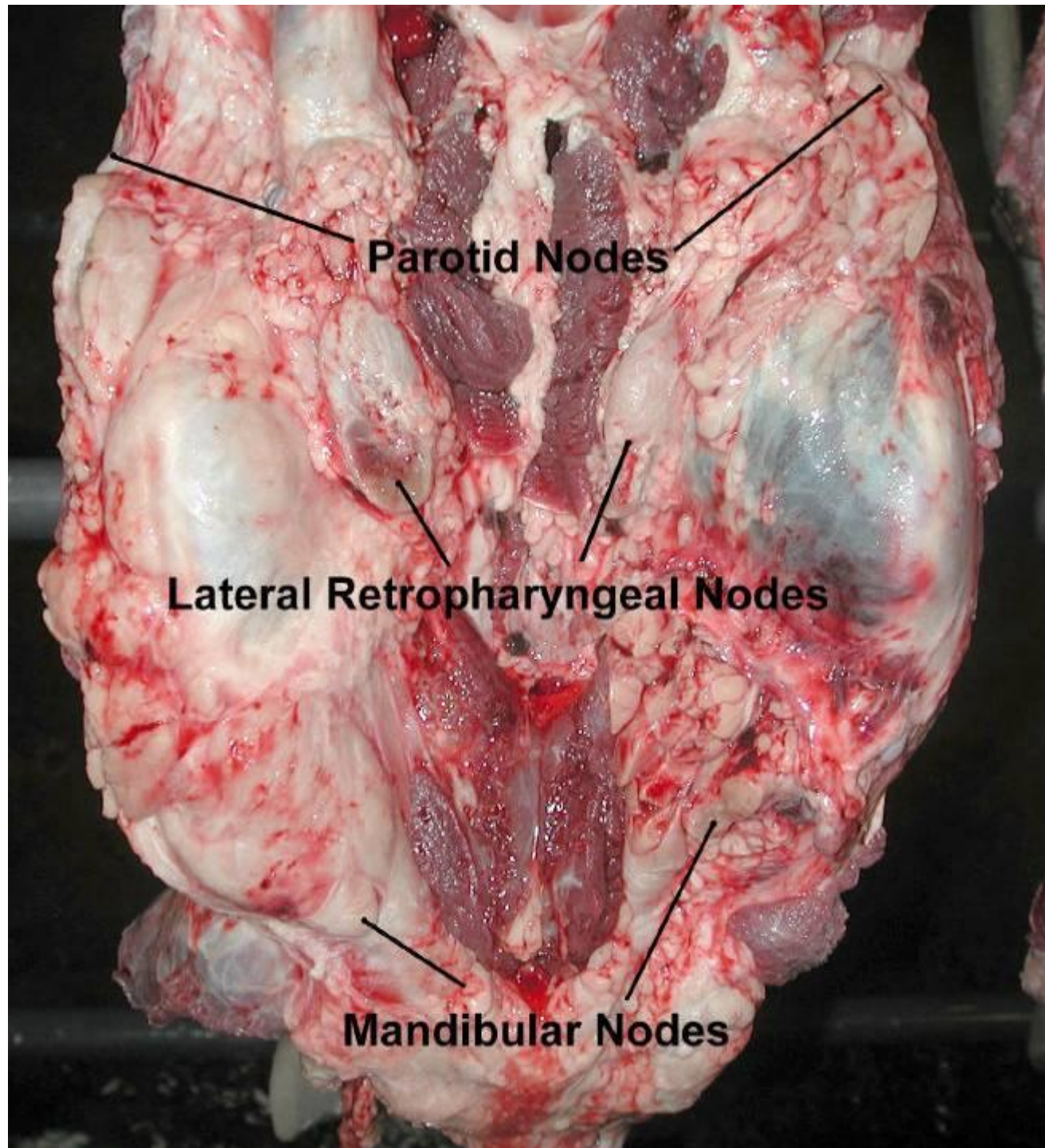
Here is the caudal
view of a beef head
seen during a
tongue-in head
presentation.



4 Major Head Lymph Nodes:

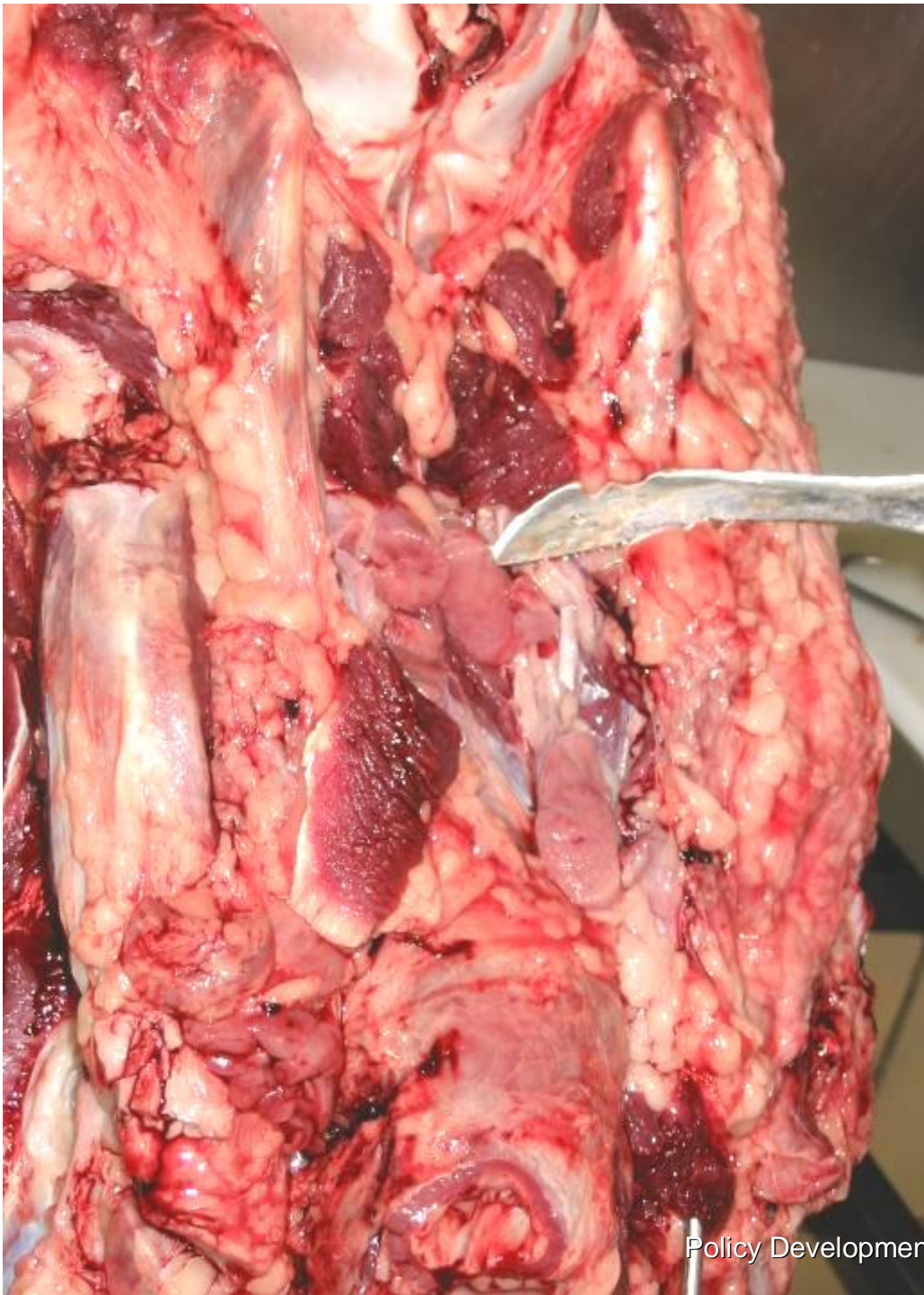1. Parotid lymph nodes (Inn.)
2. Lateral retropharyngeal lymph nodes
3. Mandibular Inn.
4. Medial retropharyngeal Inn. (below #2; not shown; see slide #20)

Another view
of three (3) of
four (4)
lymph nodes
incised
during head
inspection

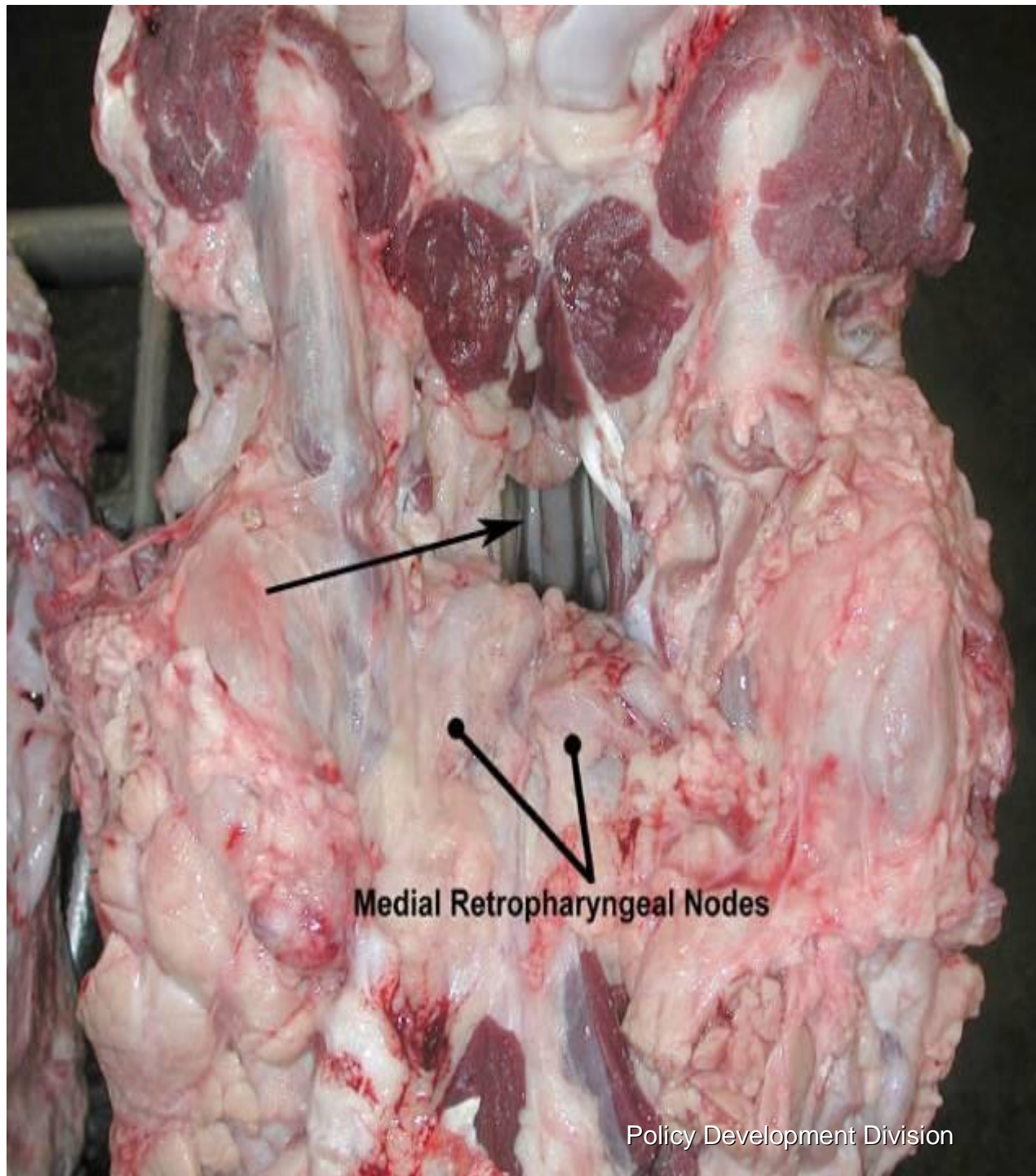


Medial Retropharyngeal Lymph nodes.

Notice they are
located just
below the muscle
(*sternothyro-
hyoideus mm.*)
tissue.



Note the opening to *nasopharynx* as indicated by presence of *pharyngeal septum* (arrow) after incision of *medial retropharyngeal Inn.*

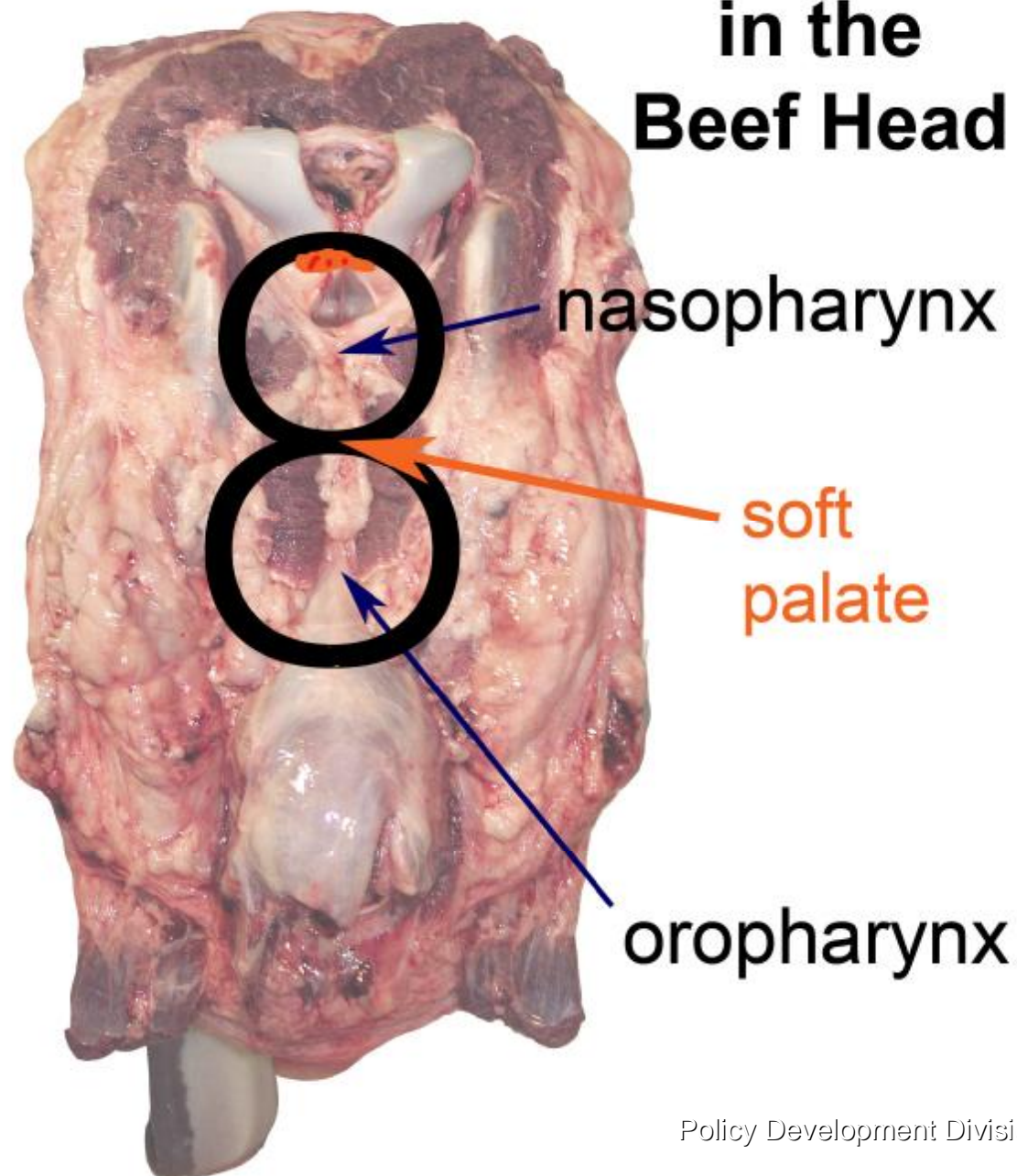




Beef Pharyngeal and Palatine Tonsils

- n The *palatine* and *lingual tonsils* are the tonsils designated as the intended SRM to be removed and are accessible through the *oropharynx*.

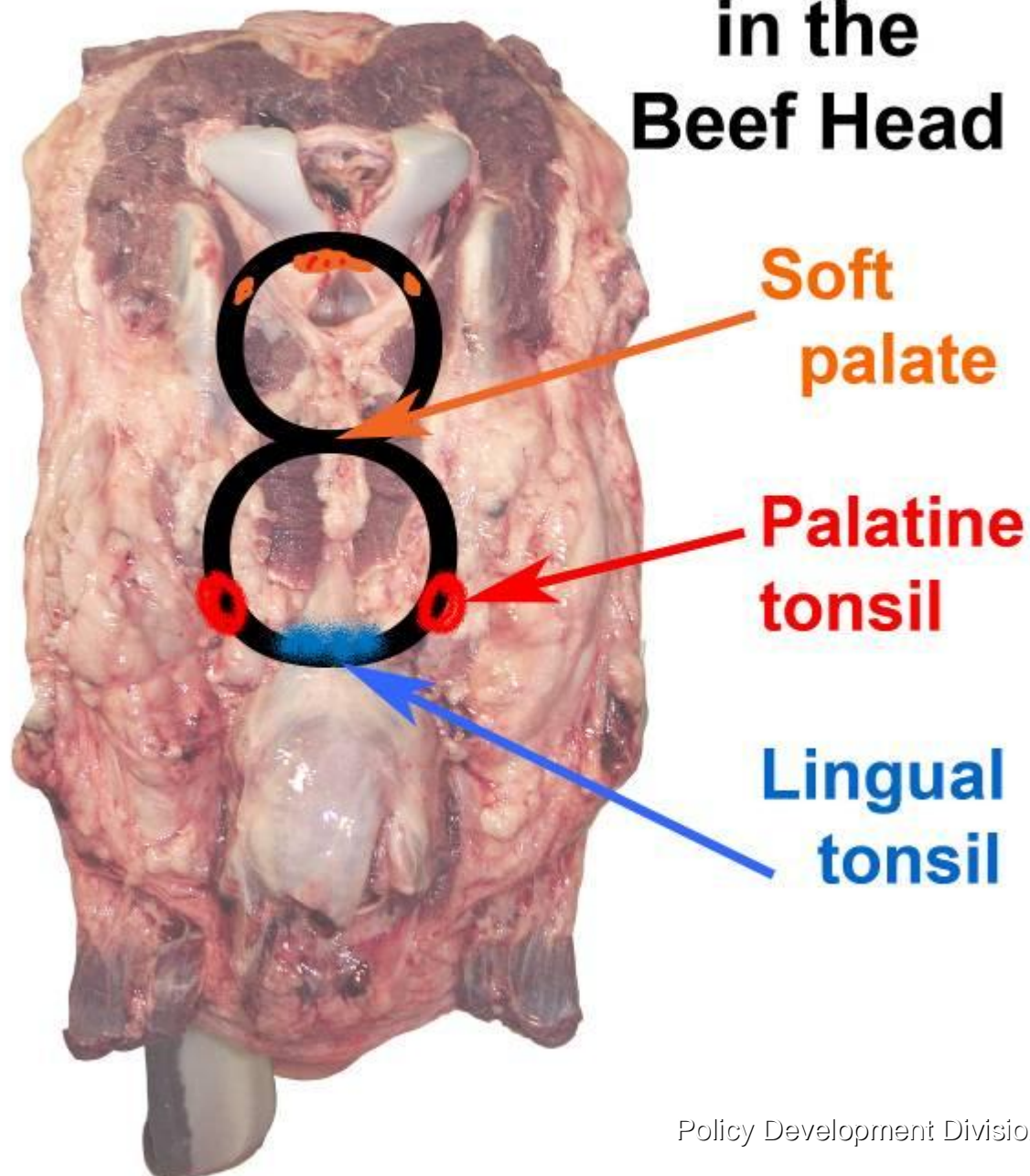
Relative Locations of Tonsils in the Beef Head



Tonsil Location

- The figure eight (8) represents the location of tonsils relative to the *nasopharynx* (above) and *oropharynx* (below).

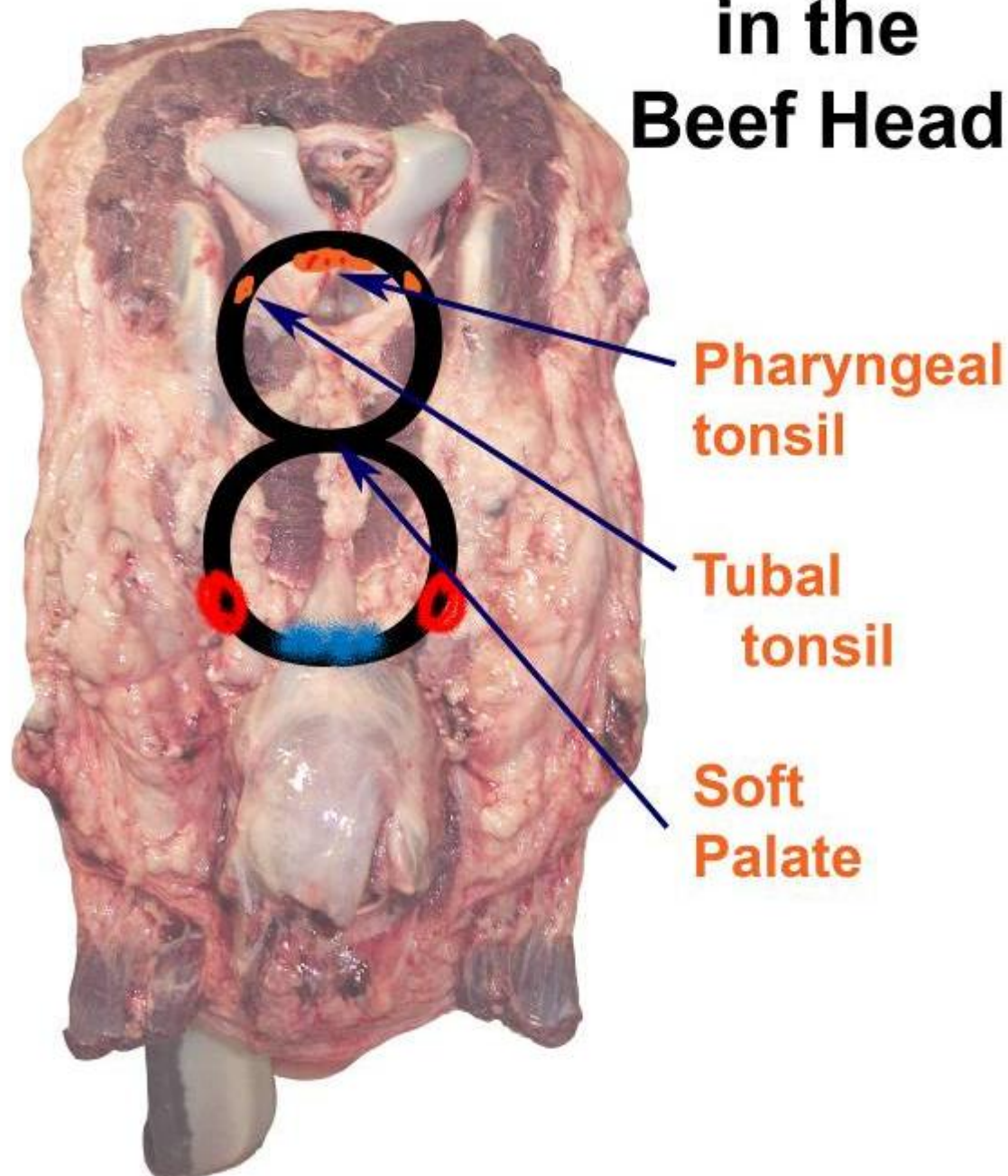
Relative Locations of Tonsils in the Beef Head



Tonsil Location

- Palatine tonsils* are at the 4 and 8 o'clock positions of the *oropharynx*.
- Lingual tonsils* are located at the base of the tongue.

Relative Locations of Tonsils in the Beef Head



- n Other tonsils including the **pharyngeal and tubal tonsils** can be found in the *nasopharynx* and need not be removed as SRM.



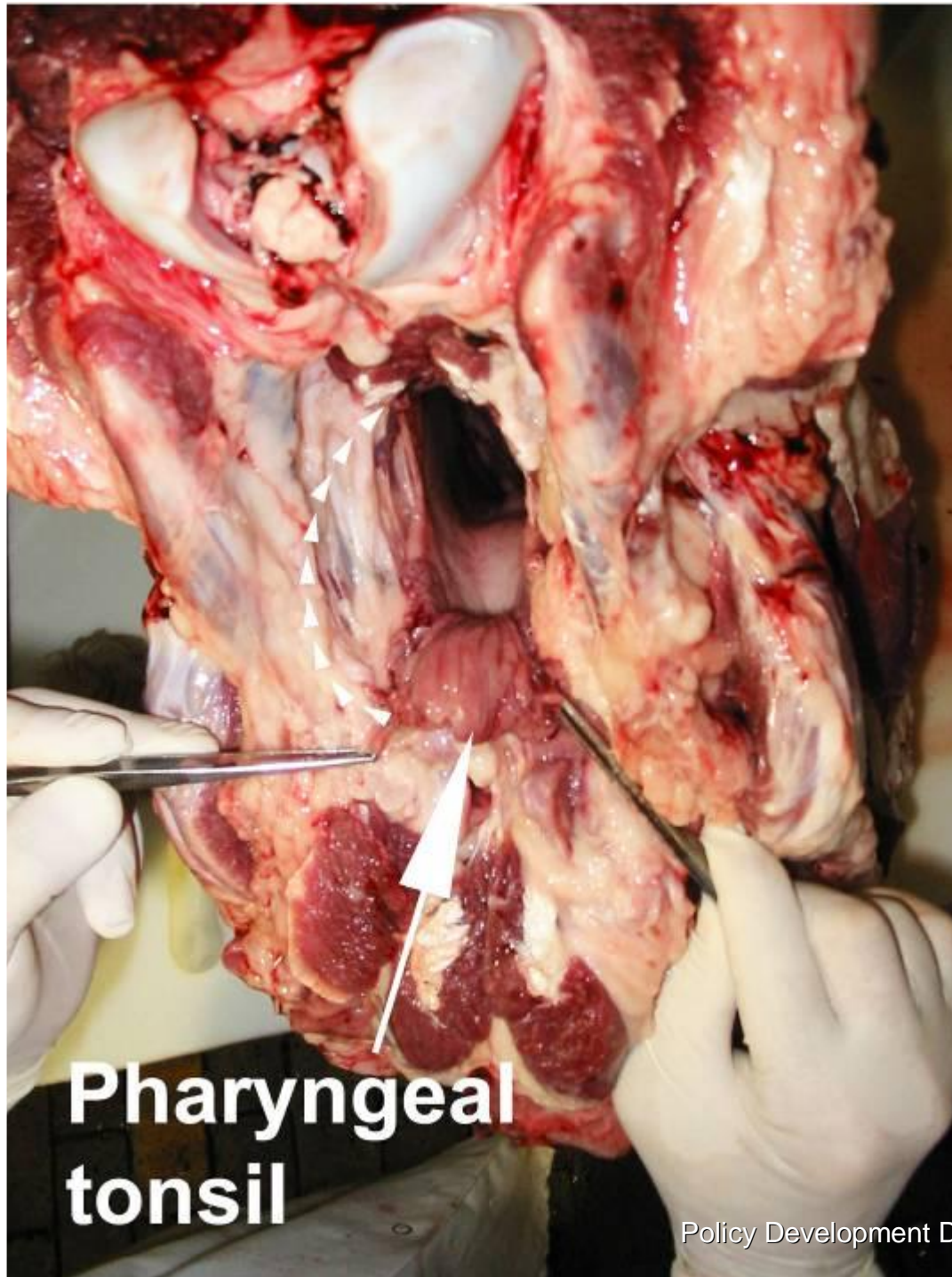
Size of Tonsils

- n The size of beef tonsils vary from animal to animal depending on two (2) major factors:
 1. age (younger>>larger tonsils) and
 2. reactivity to antigenic stimulation (reactive>>larger tonsils).



Pharyngeal Tonsils

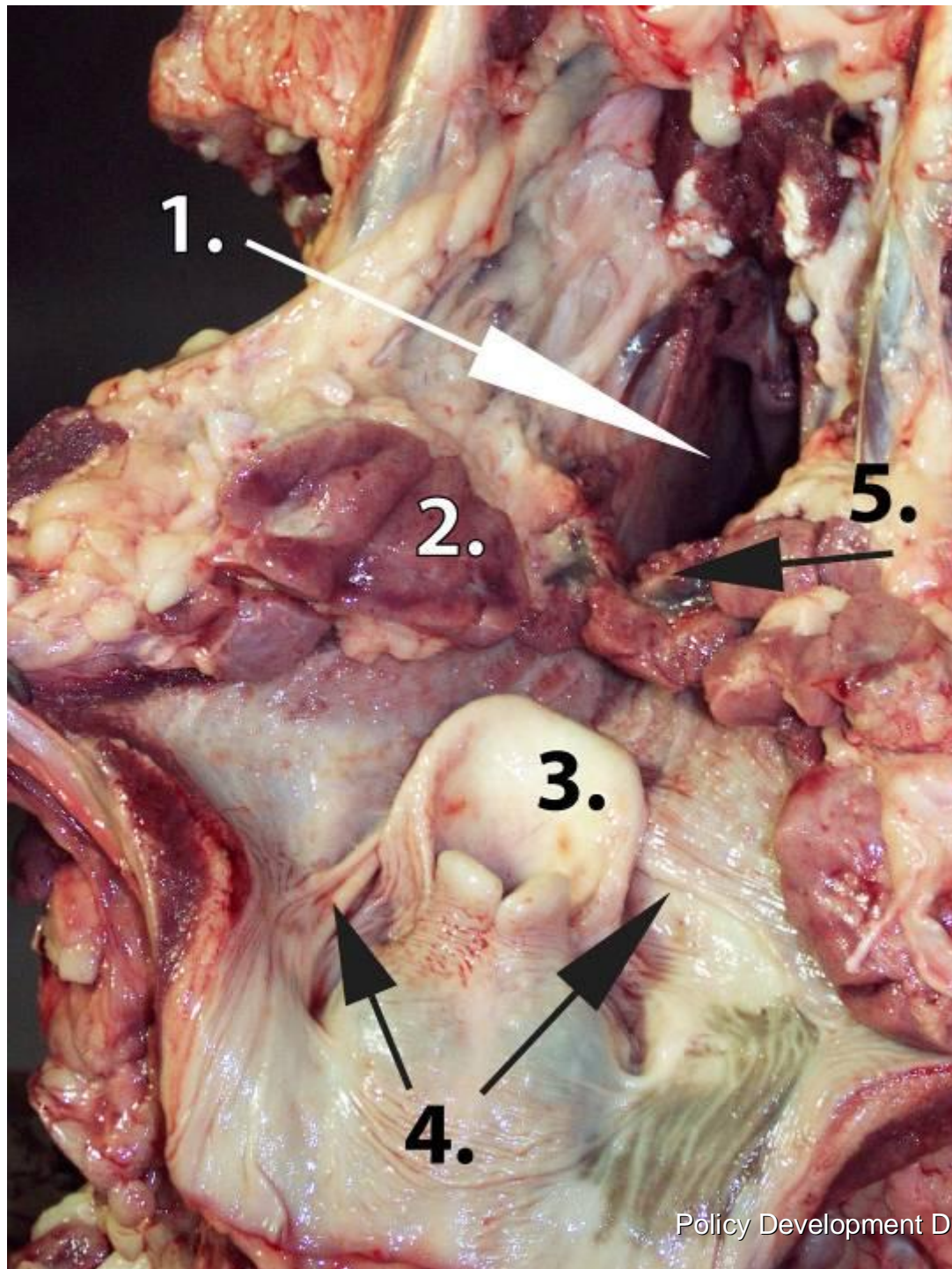
- n Pharyngeal tonsils are mentioned here only for anatomical reference.*
- n Pharyngeal tonsils*, located at the roof of the nasopharynx, tend to be larger and less inflamed (congested) than other tonsils.
- n Pharyngeal tonsils* have a soft folded appearance



**Pharyngeal
tonsil**

Here is the
pharyngeal tonsil
reflected
downward after
opening of the
nasopharynx.

Note its soft folded
appearance.



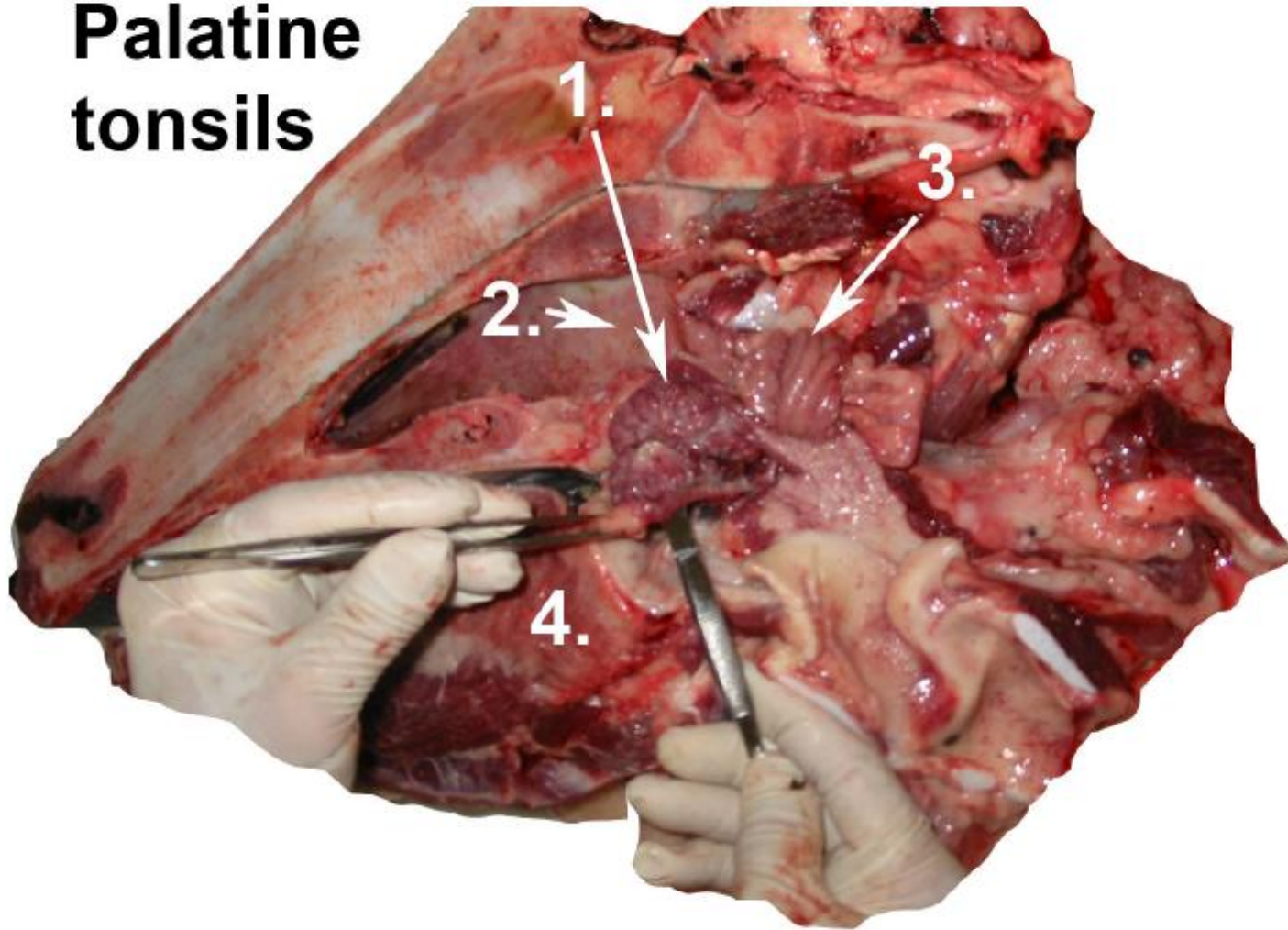
1. Nasopharynx
2. Medial retropharyngeal lymph node (incised)
3. Epiglottis
4. Edge of the soft palate or the *palatopharyngeal arch*
5. *Pharyngeal tonsil*



Palatine Tonsils

- n Located adjacent to *soft palate* below the mucosal surface and the opening of *sinus of palatine tonsil*.
- n Note: *Palatine tonsils* tend to be larger, more congested, and inflamed at post mortem. As the length of post mortem increases, these tonsils tend to be less congested.

Palatine tonsils



1. Palatine tonsil

3. Pharyngeal tonsil

2. Nasopharynx

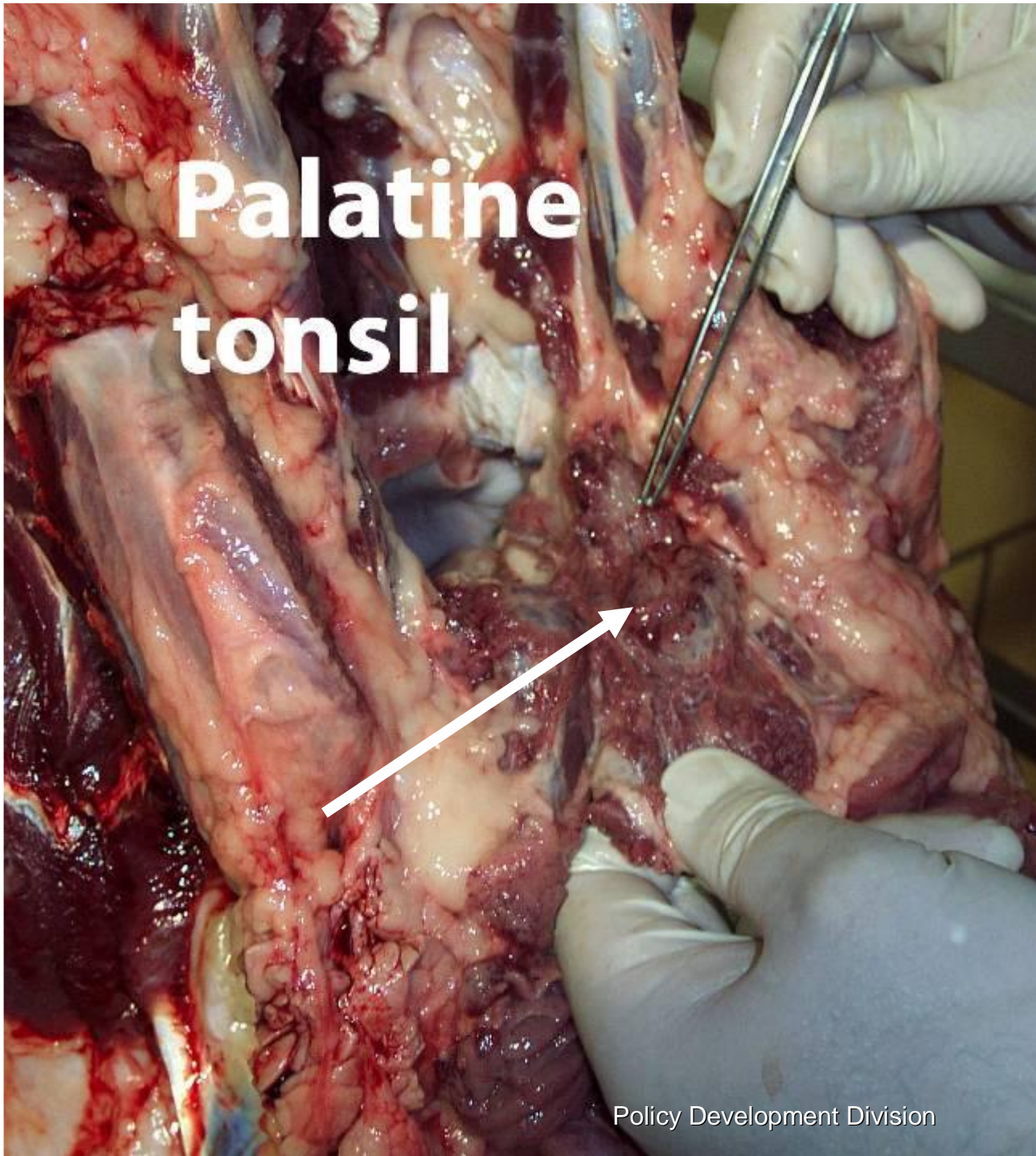
4. Tongue



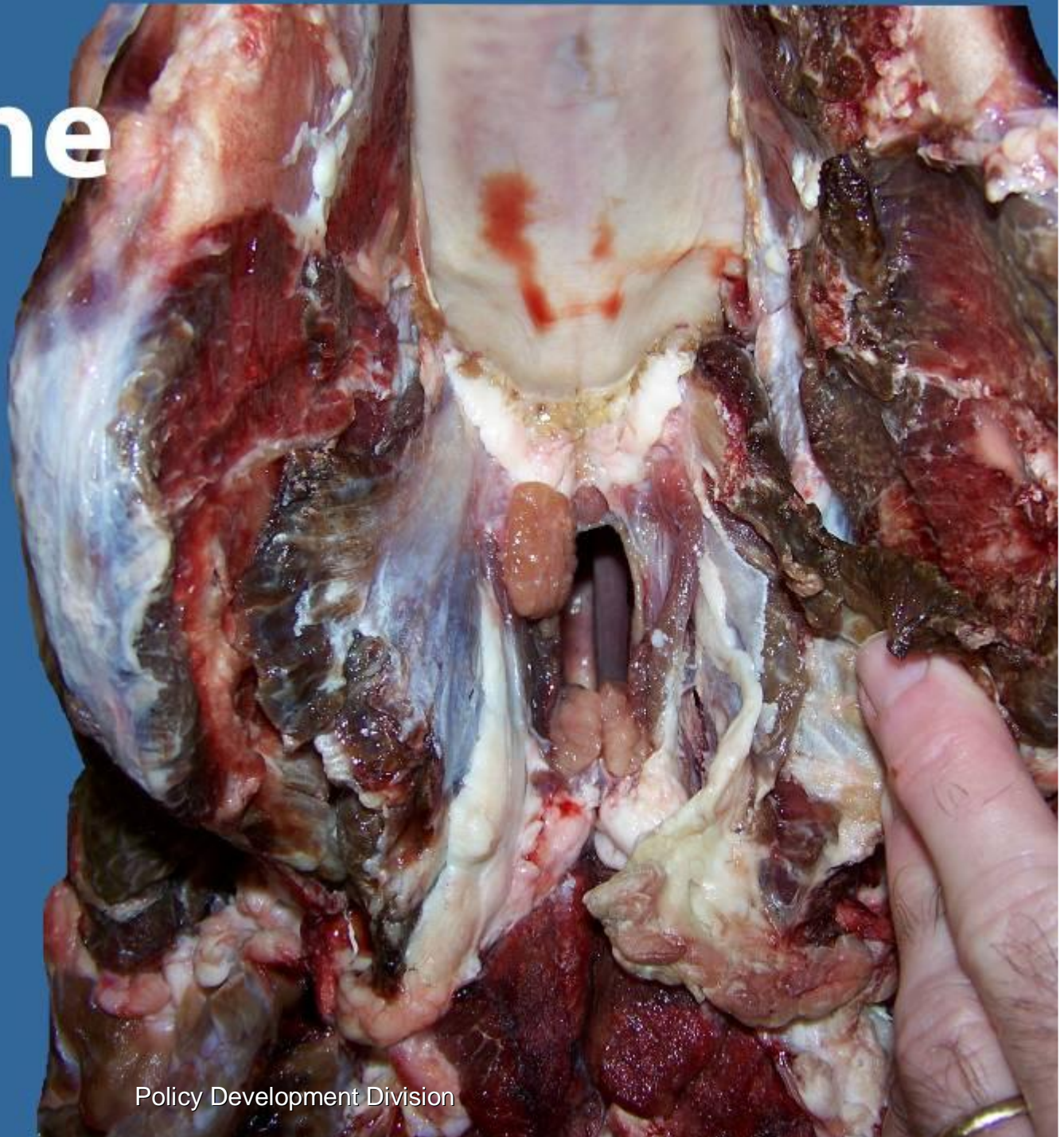Palatine tonsil

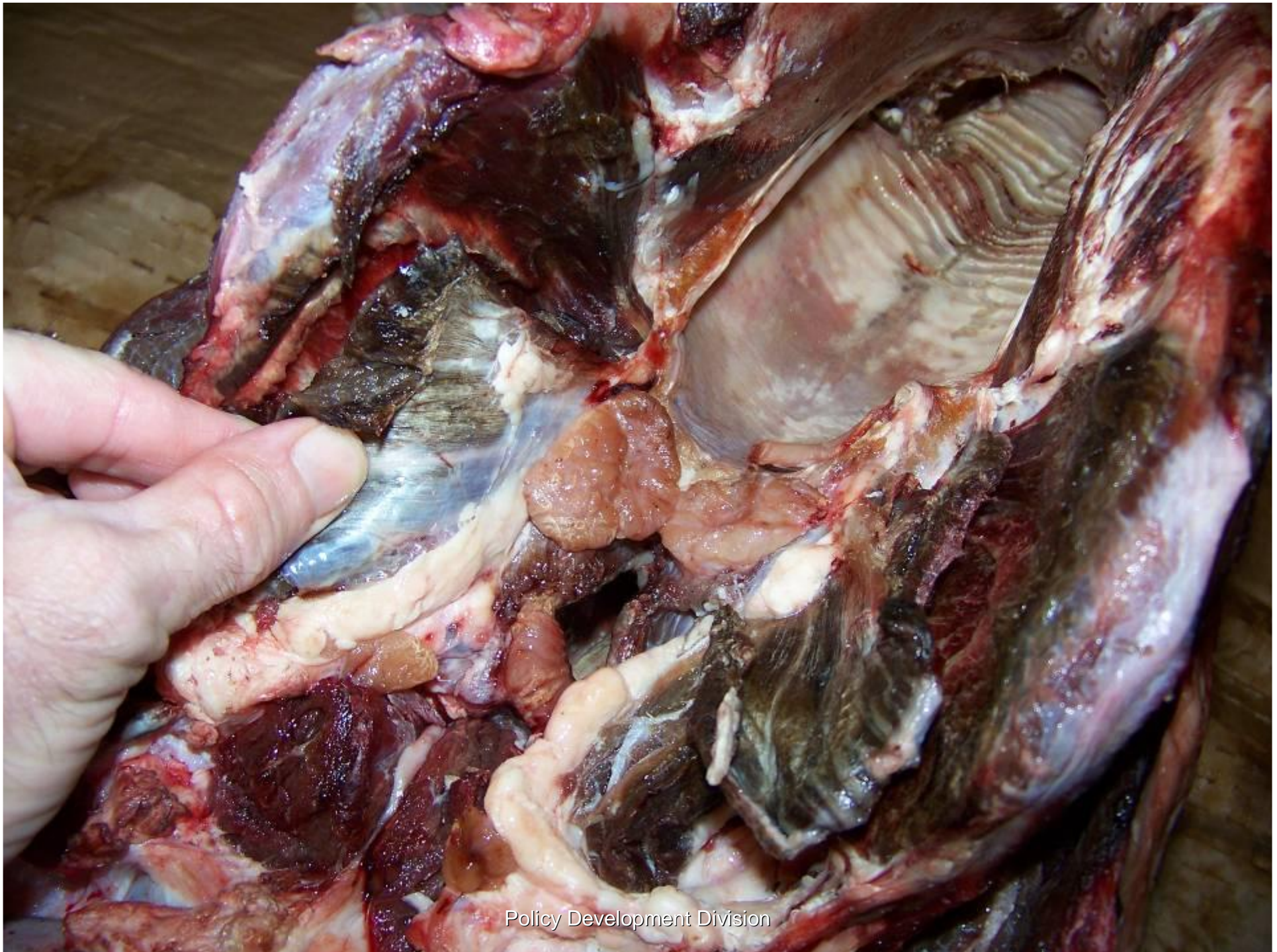
Note the *congested* appearance below the mucosal surface.

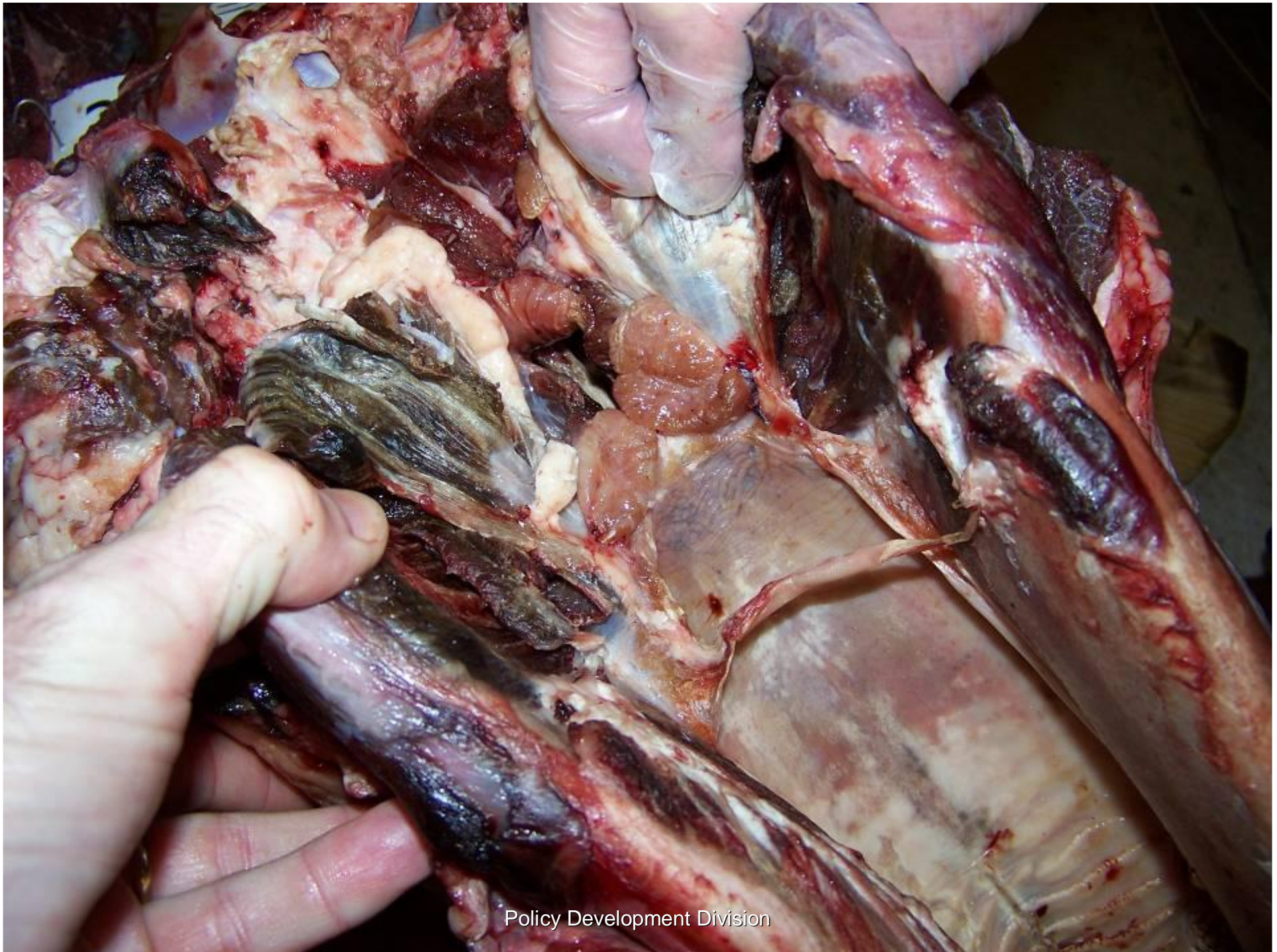
The arrow points to the *palatine tonsil* and congestion around it.



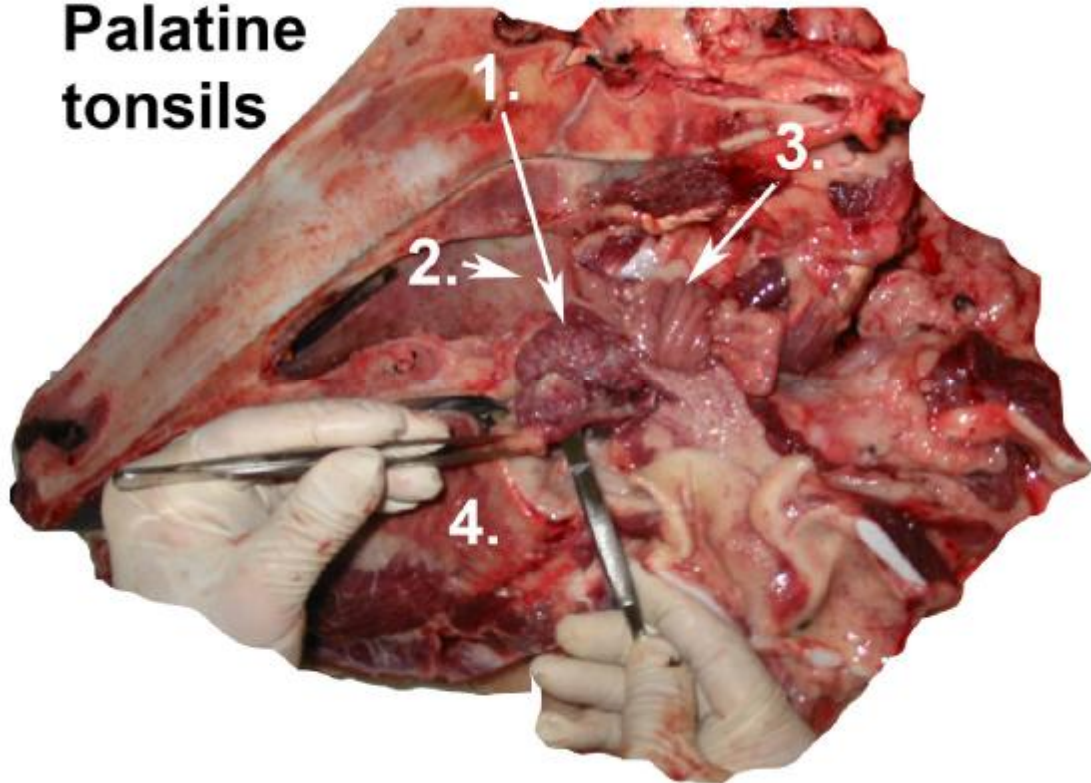
Palatine tonsil







Palatine tonsils

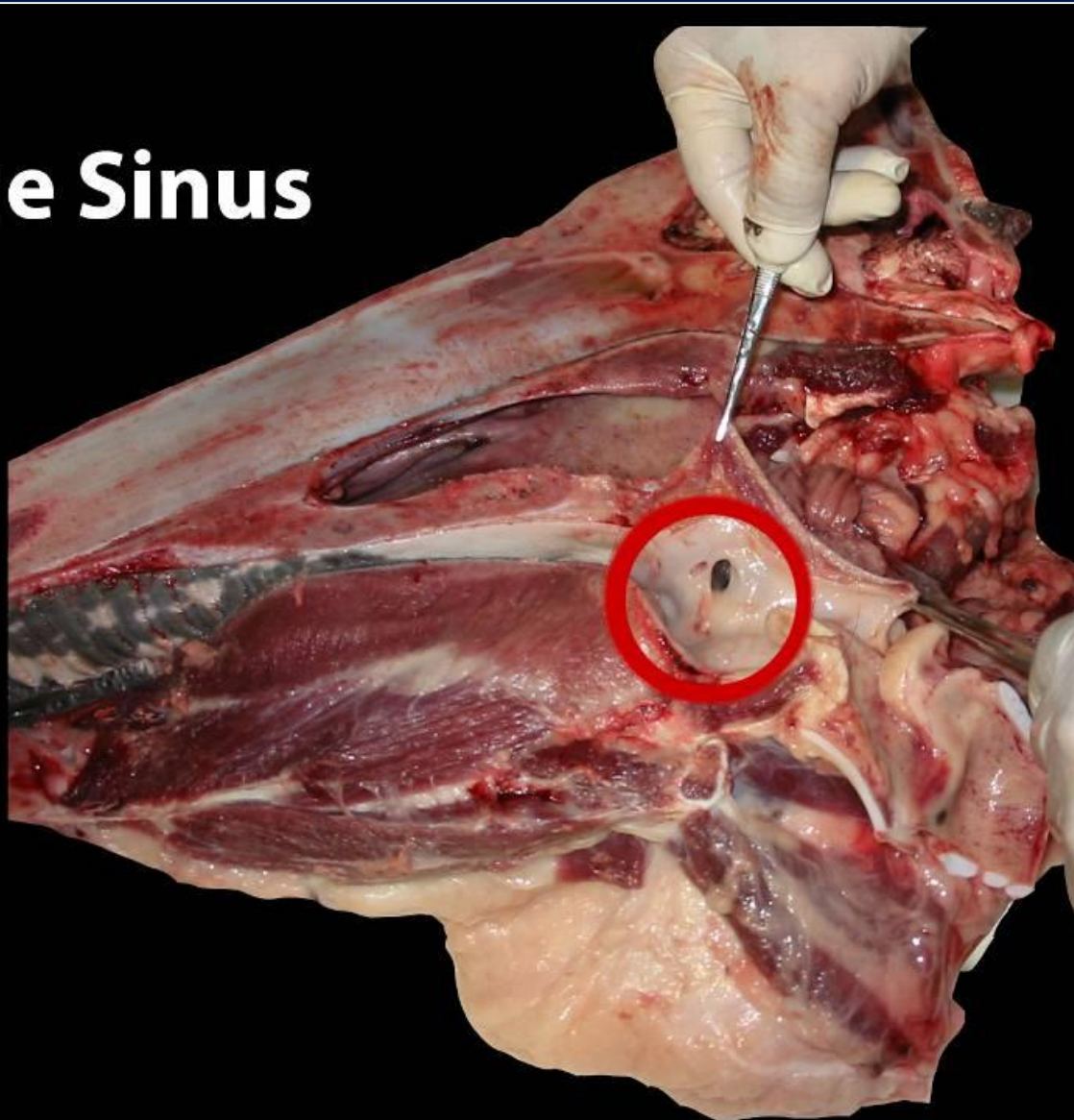


Note:

The probe is directed at the *palatine tonsil* (1) into the opening to the *sinus of the palatine tonsil* lateral to base of the tongue (4).

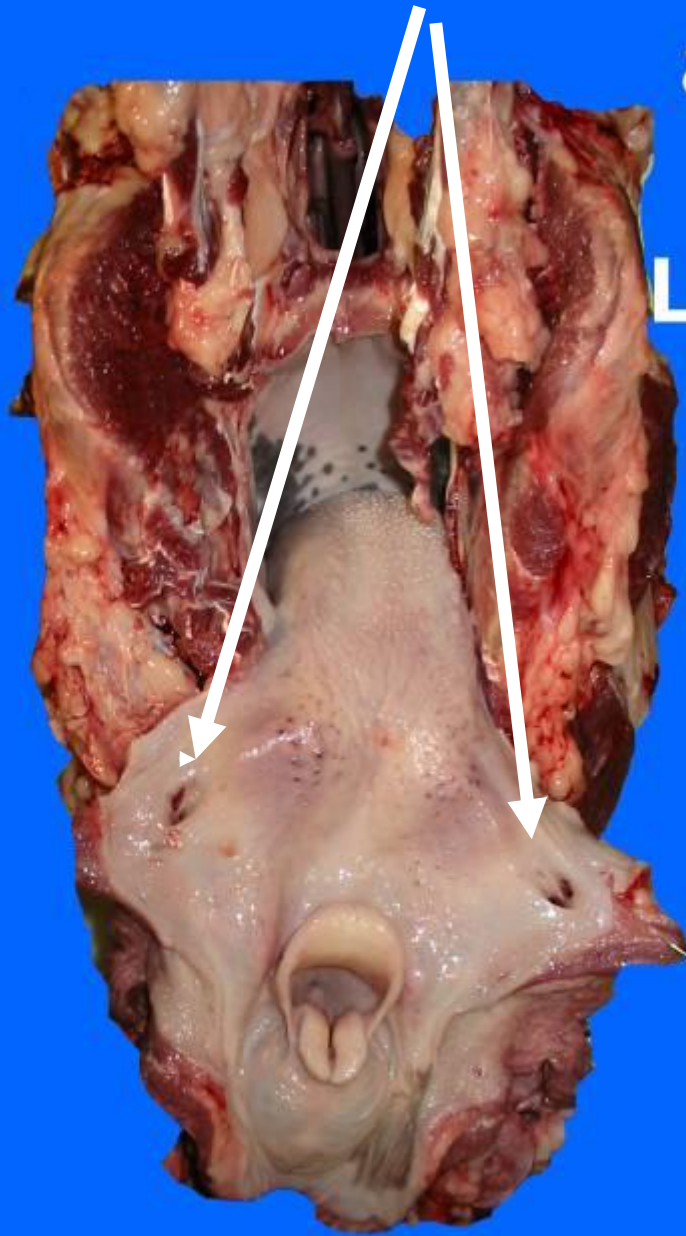
The *pharyngeal tonsil* (3) has sagged into the nasopharynx (2).

Palatine Sinus



Palatine Sinuses and

Lingual tonsils

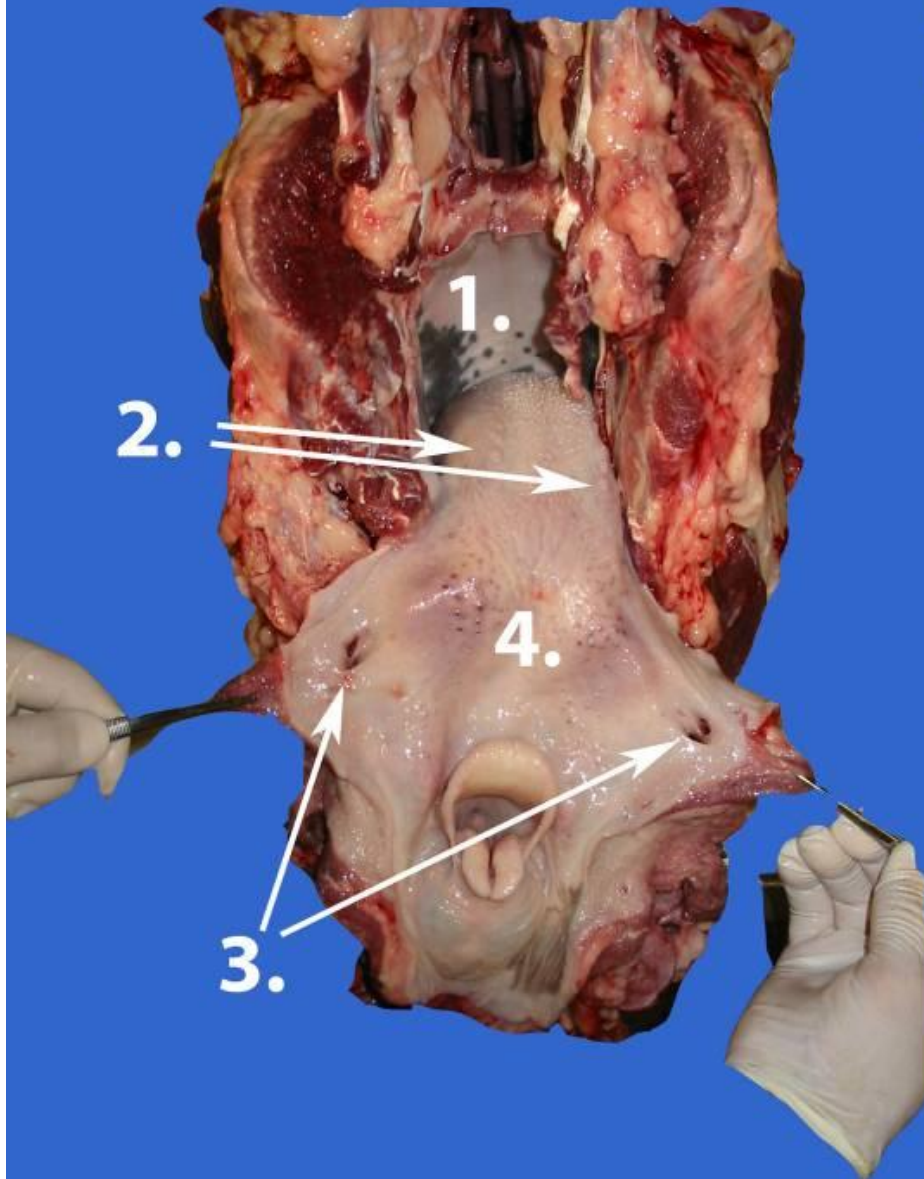


Note: The opening to *sinus of the palatine tonsil* (arrows) is a useful landmark for locating the *palatine tonsil*.

Lingual and Palatine tonsils

Note the following:

1. hard palate
2. vallate papillae
3. sinus of the palatine tonsil
4. lingual tonsils

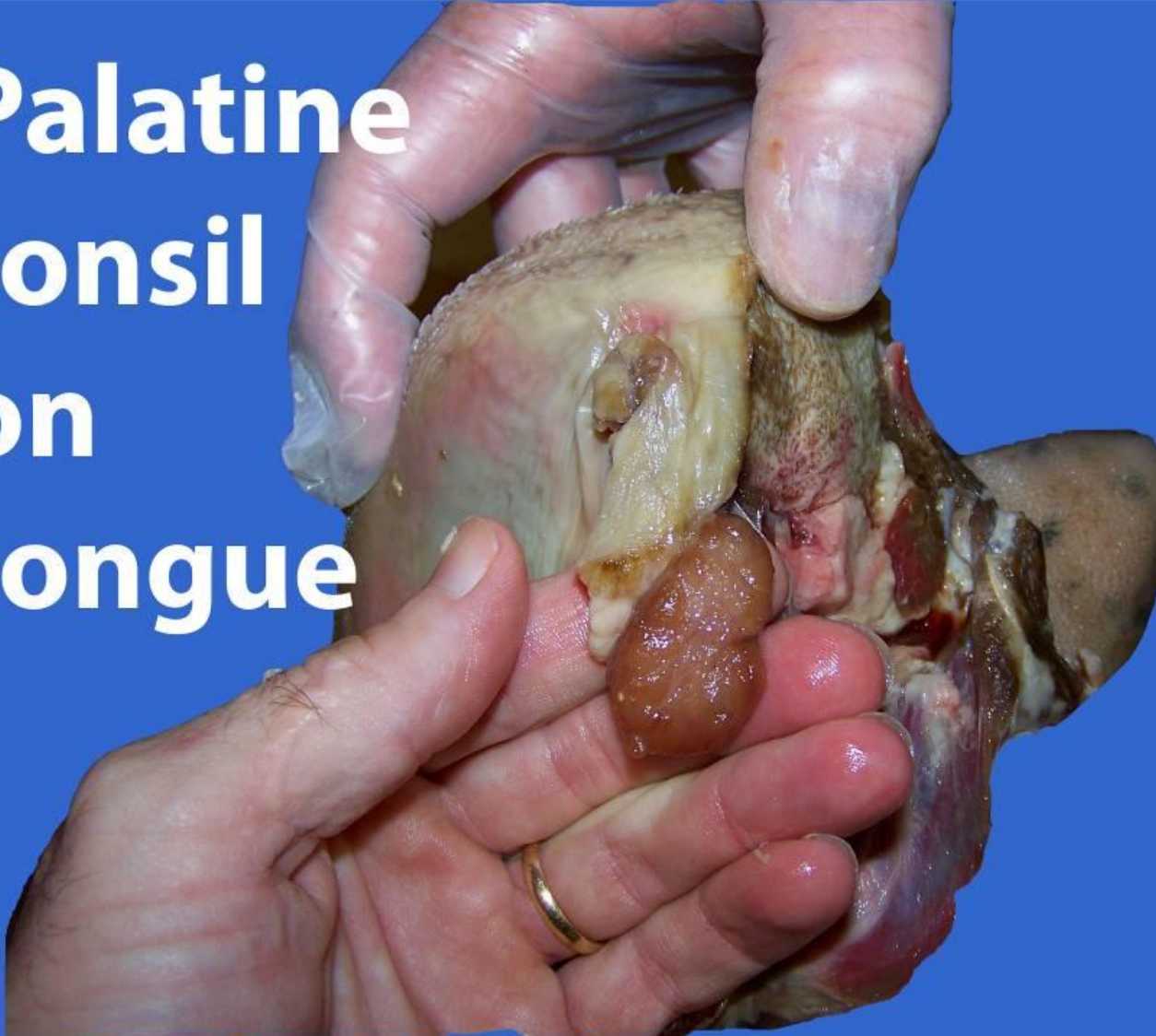

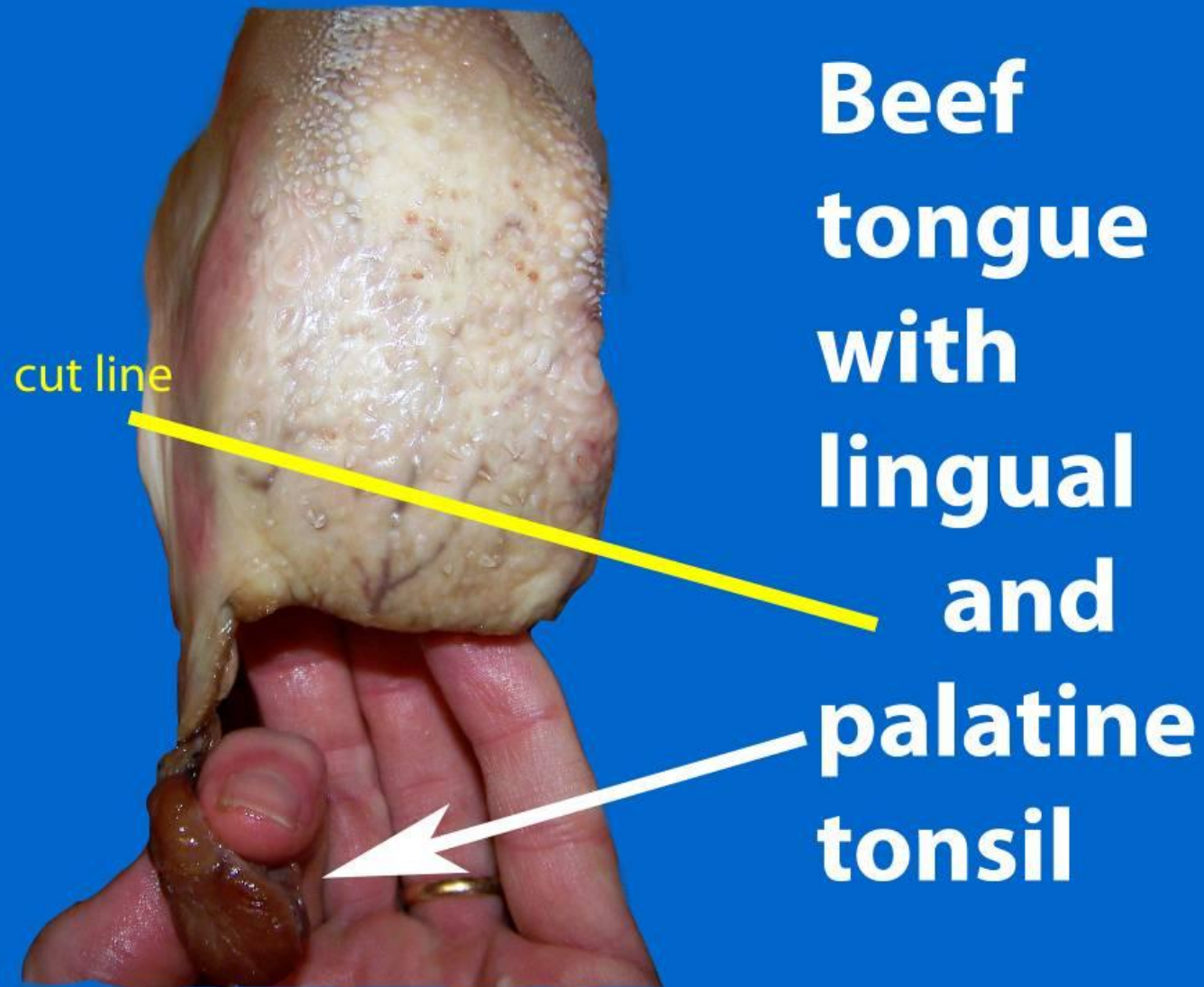


Beef Tongue and Palatine Tonsils

- n Depending on how the tongue is removed from the head, the *palatine tonsil* may be found attached to remnants of the beef tongue.

Palatine tonsil on tongue



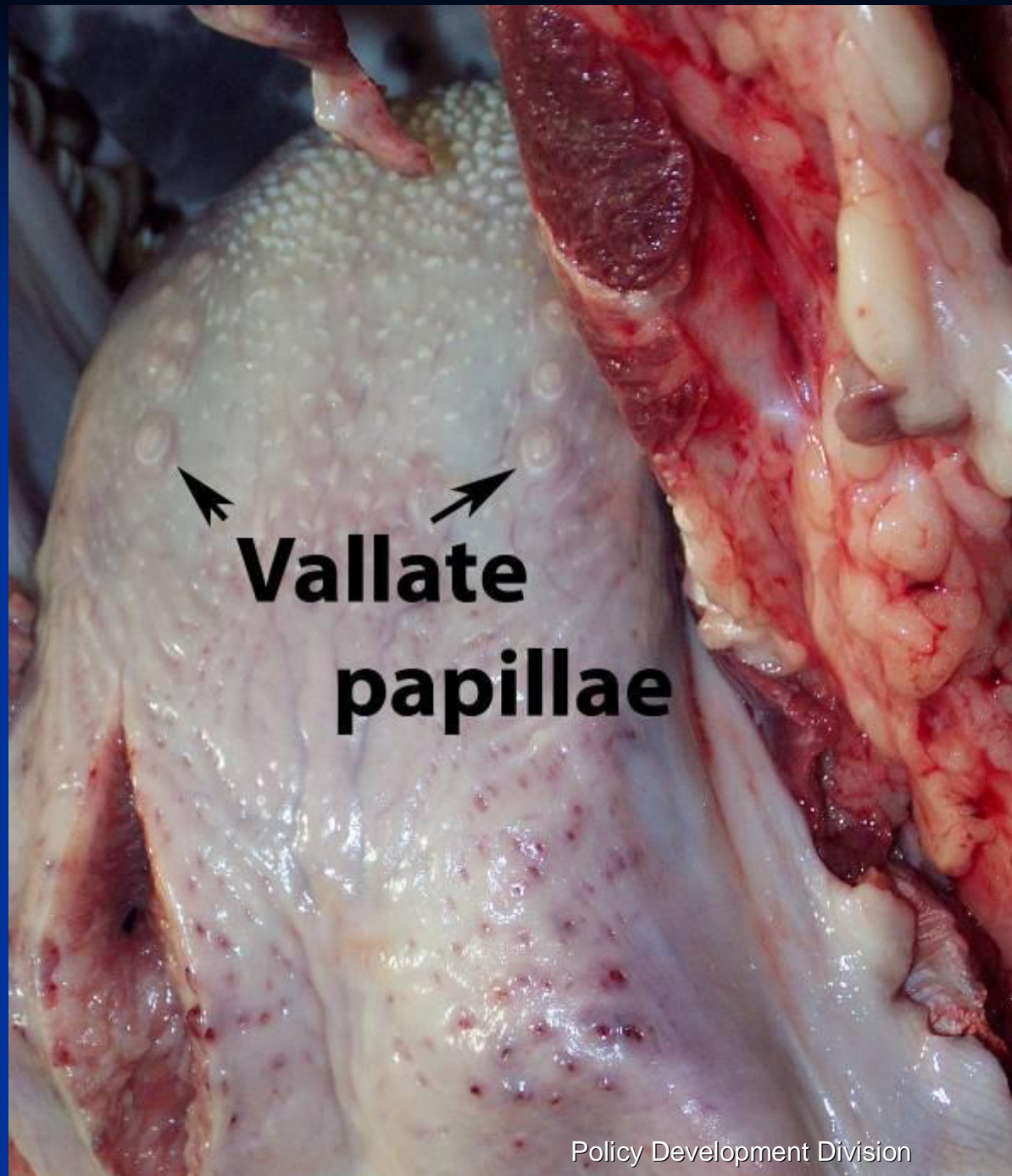


Note:
Lingual
tonsil to be
removed is
located
below the
yellow cut
line.



Lingual Tonsils

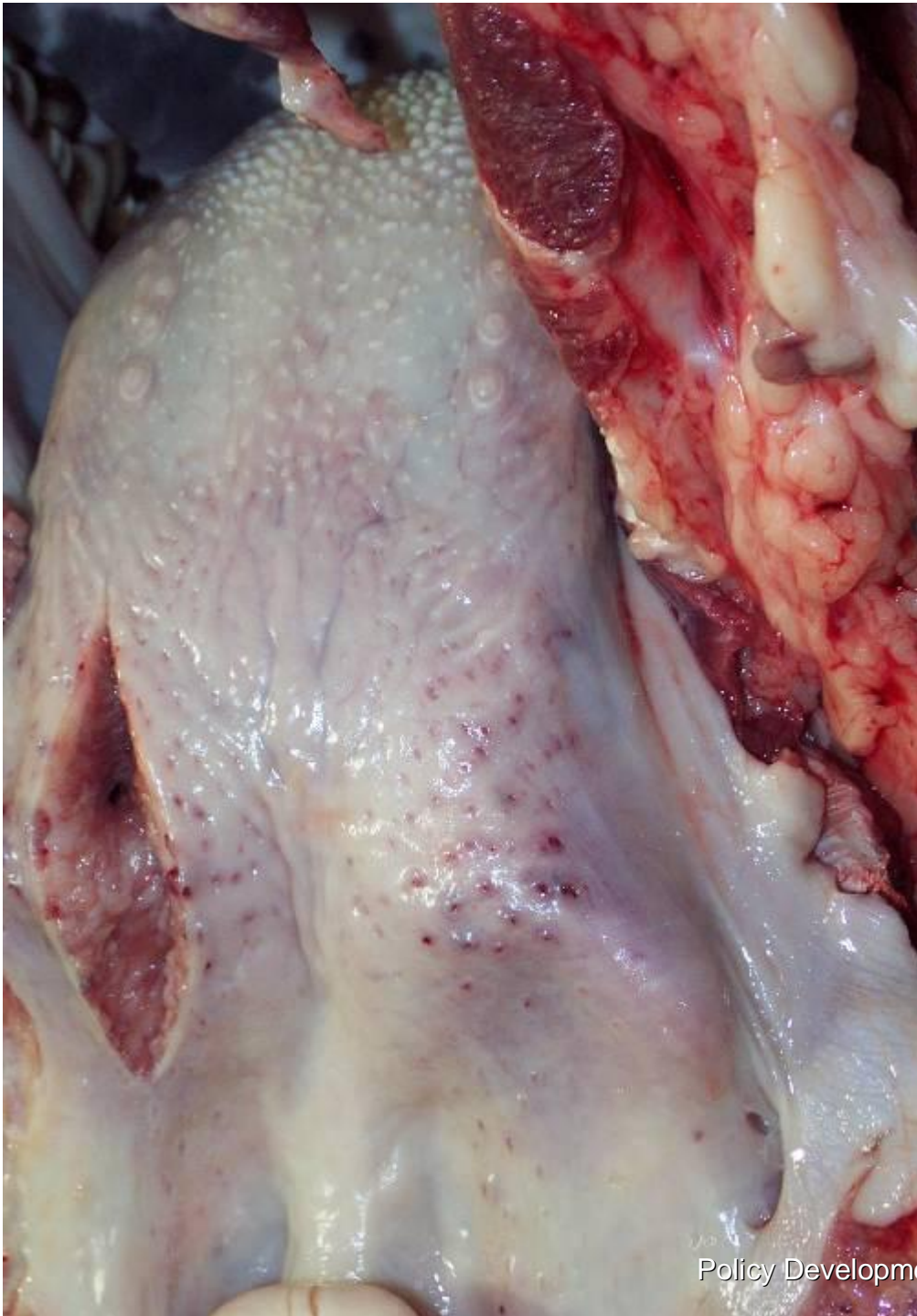- n Located at the base of the tongue
- n *Lingual tonsils* are removed by removing the epithelium and underlining muscle to a sufficient depth (~>5mm) just caudal to the last *vallate papillae* by knife trimming or skinning.

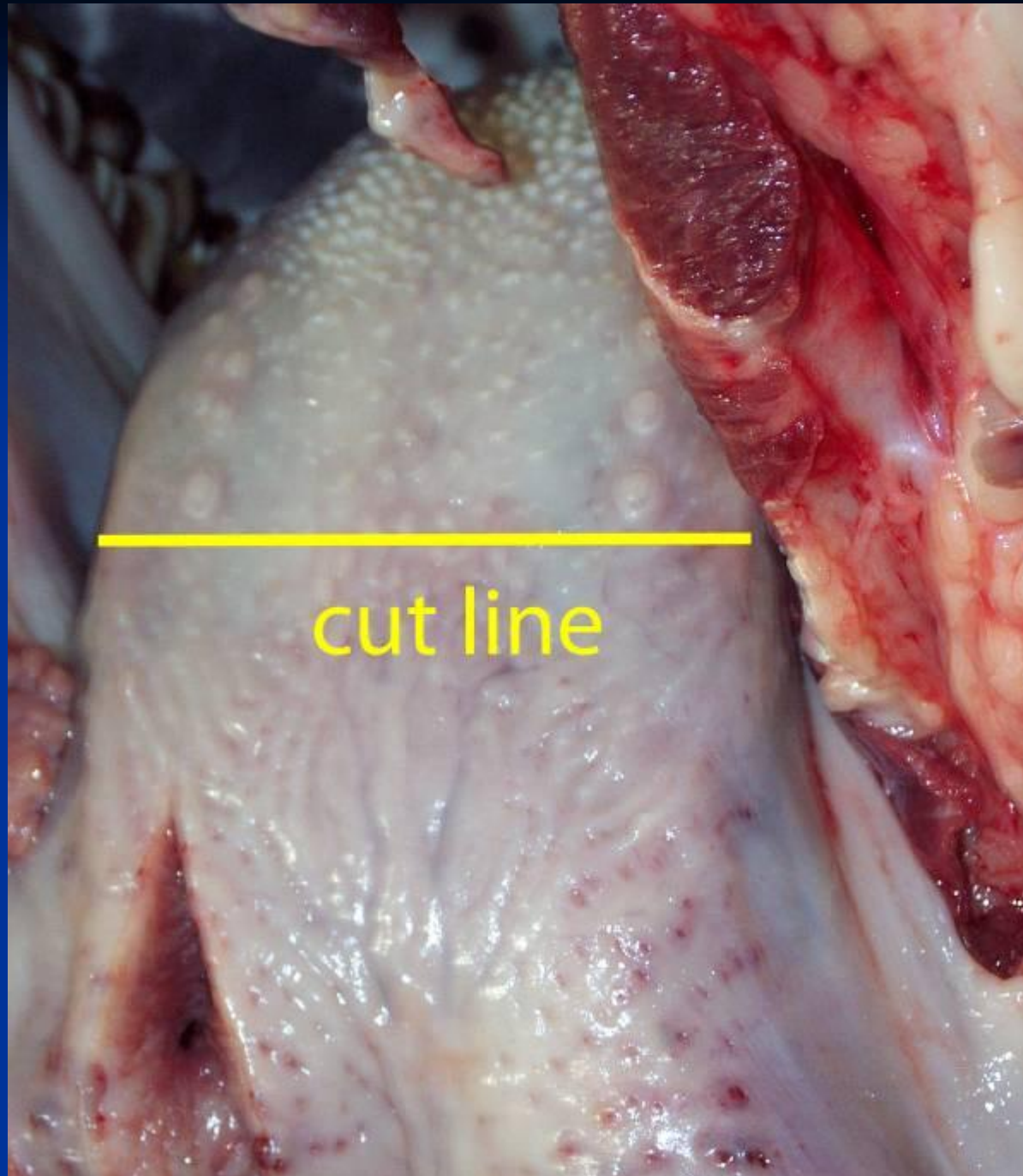


Lingual Tonsils

Lingual Tonsils

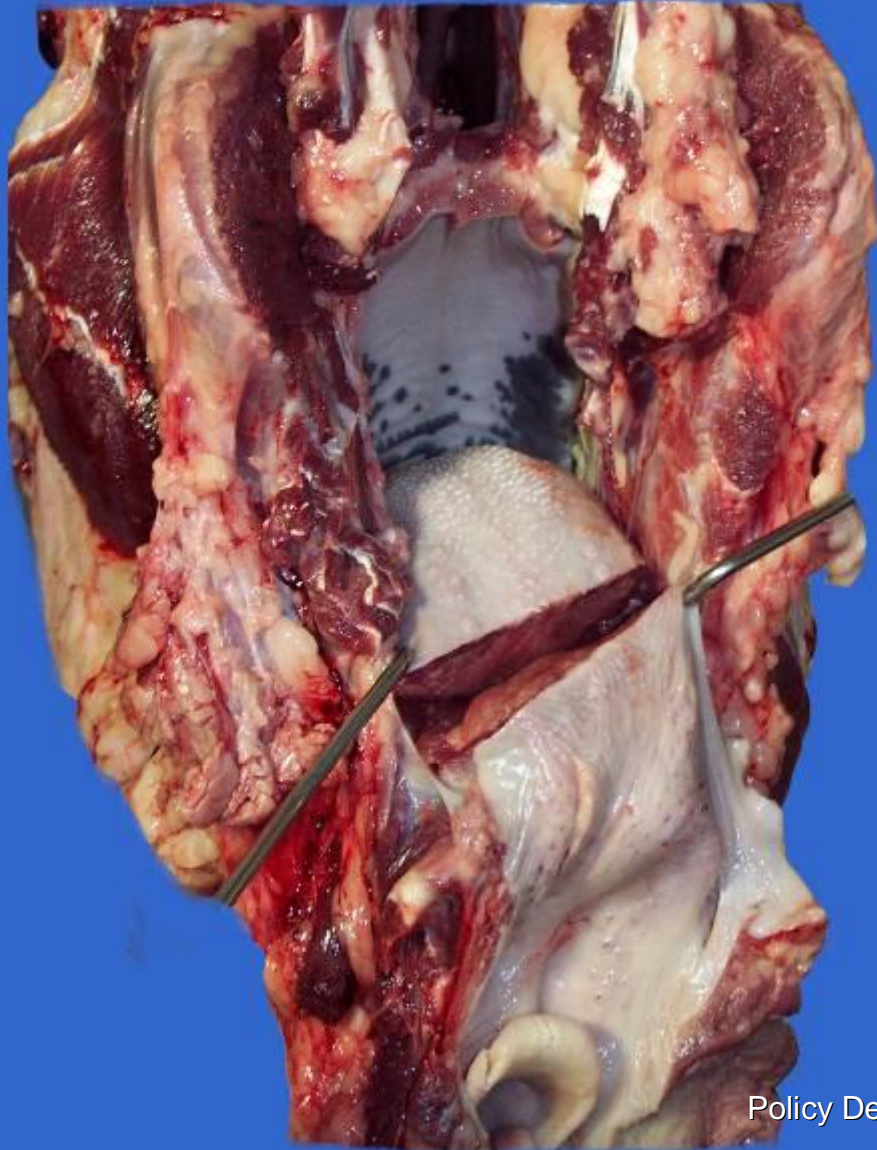
- n Can you identify the vallate papillae and location of lingual tonsils in this picture?
- n Answer: See the next slide.





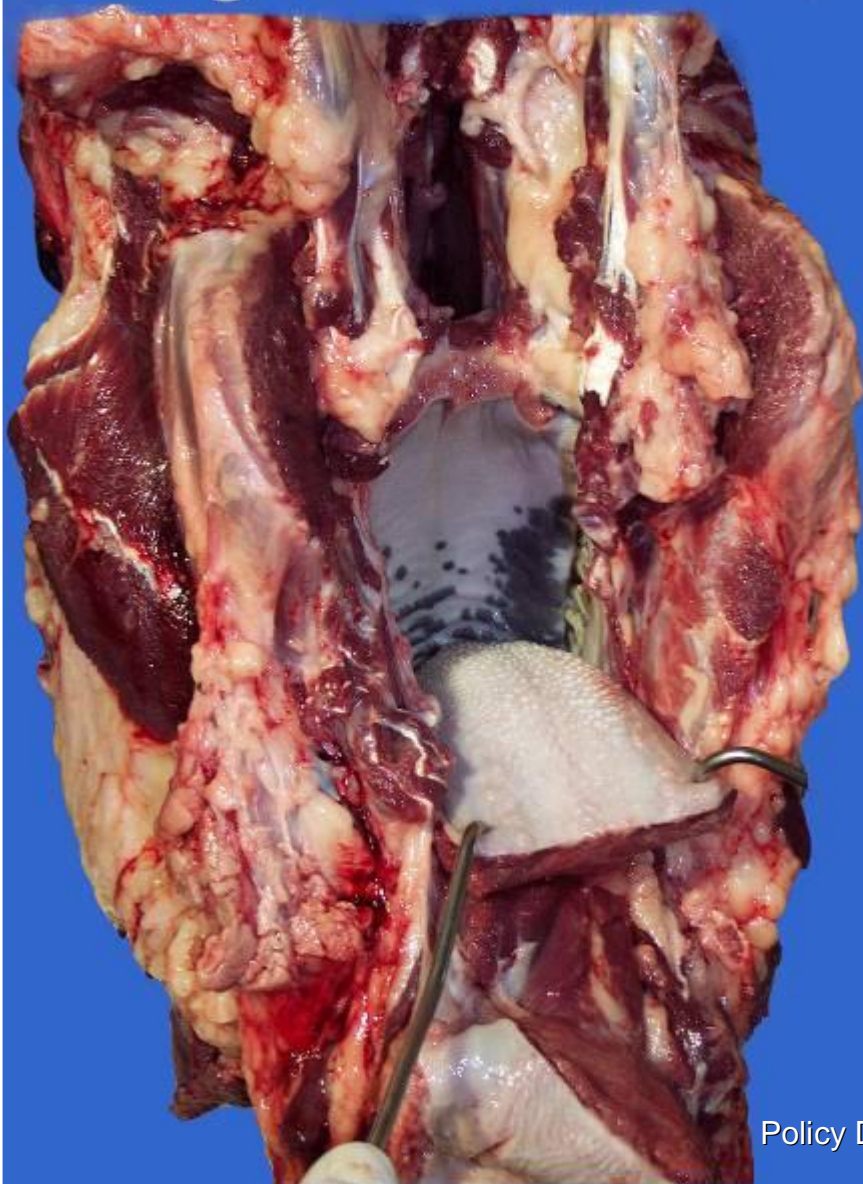Beef tongues are adequately trimmed when the surface layers are removed to a sufficient depth (~>5mm) caudal to the last *vallate papillae*.

Removal of Lingual tonsil



Removal of
lingual tonsils in
a beef market
head.

Removal of Lingual tonsil



Removal of
lingual tonsils in a
beef market
head.

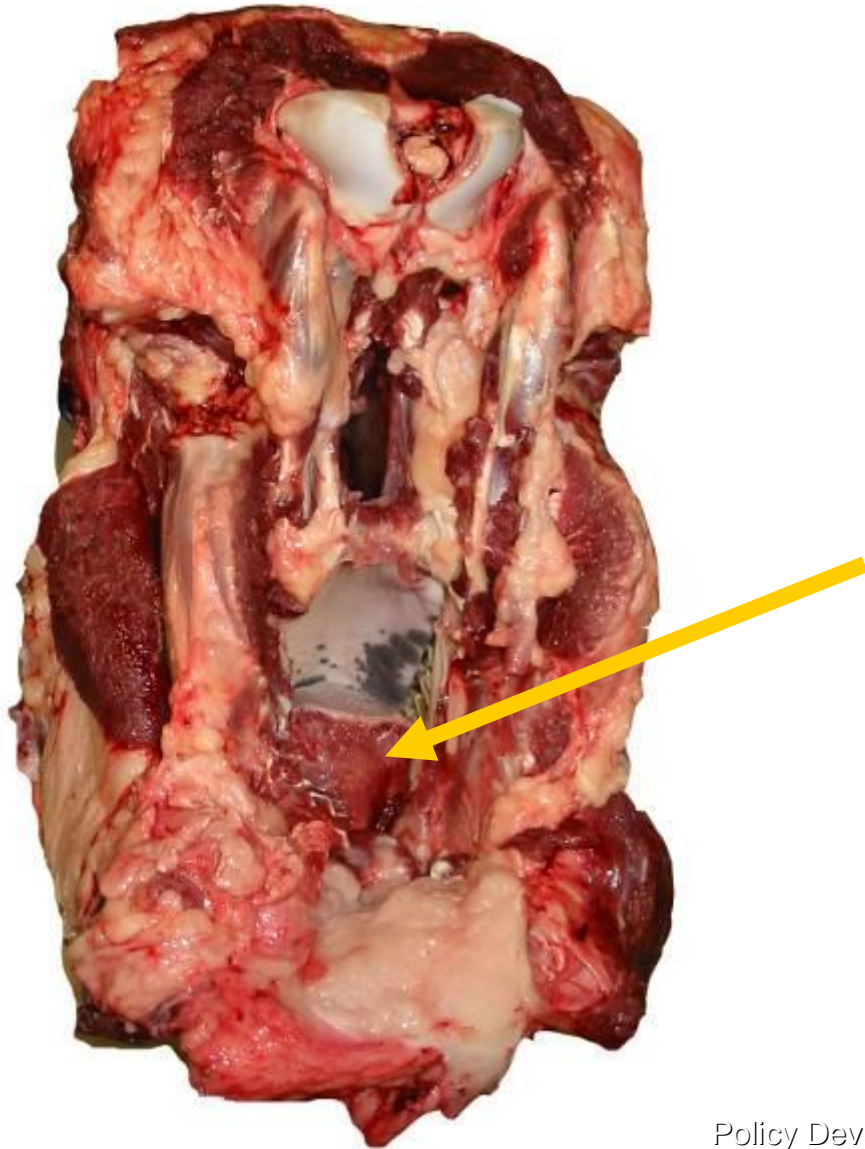
Note: Less
radical removal
leaving more
tongue meat is
also acceptable.



Beef Market Head sans Lingual and Palatine Tonsils

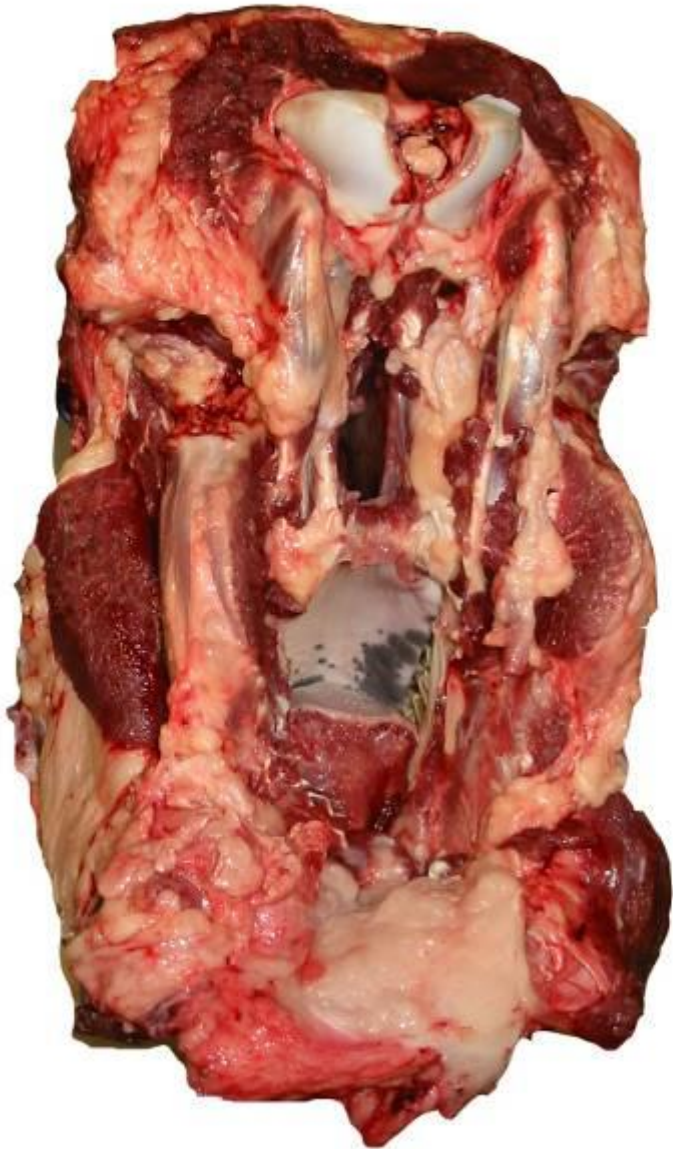
- n Removal of the palatine and associated lingual tonsils of a beef market head meet the requirements of 9 CFR 310.22 regarding removal of SRM tissue.

Beef Market Head



Here is a beef market head with all tonsil related SRM removed. The **arrow** points to the short cut tongue in situ.

Beef Market Head



Policy Development Division



A beef market head with all tonsil related SRM removed is eligible for the mark of inspection and can enter commerce.



Questions?

Please submit your tonsil or SRM questions to one of the following:

1. AskFSIS at <http://askfsis.custhelp.com>

OR

2. Contact the Policy Development Division (PDD) (formerly the TSC) at 1-800-233-3935.