

## Para Esophageal Hernia in the Neonatal Period: Suspicion on Chest X-ray

**Ram Samujh**  
**Devendra Kumar**  
**K.L.N. Rao**

*The paraesophageal hernia is rarely seen in the neonatal period. Presentation in neonatal period can be confused with the possibility of esophageal atresia or esophageal web. The upper gastrointestinal tract contrast study is diagnostic in this disease, but careful viewing of the plain X-ray of the chest can also lead to suspicion of the diagnosis. Two neonates with para-esophageal hernia are reported, one with the mesenterico-axial volvulus and the second neonate without volvulus.*

**Key words:** *Newborn, Para-esophageal hernia.*

Paraesophageal hernia consists of displacement of the stomach into the thoracic cavity alongside the esophagus, which remains in its normal position. This is an anatomical defect of the hiatus without any derangement of the gastroesophageal sphincter, which clearly distinguishes it from other types of hiatal hernia. Anderson(1) reported paraesophageal hernia to be rare in children, particularly in the neonatal period.

---

*From the Department of Pediatric Surgery, Advanced Pediatric Center, Postgraduate Institute of Medical Education and Research, Chandigarh 160 012, India.*

*Correspondence to: Dr. Ram Samujh, Associate Professor, Department of Pediatric Surgery, Advanced Pediatric Center, Postgraduate Institute of Medical Education & Research, Chandigarh 160 012, India. E-mail: rsamujh@yahoo.com*

*Manuscript received: April 25, 2003;  
 Initial review completed: June 6, 2003;  
 Revision accepted: June 26, 2003.*

The problems of gastro-esophageal reflux and sliding hernia in pediatric age group overshadow the pathology of the esophageal hiatus of the diaphragm in this age group. Its presentation in neonatal period can be confused with the possibility of esophageal atresia(2), or esophageal web. The contrast study for esophagus and stomach is diagnostic in this disease, but careful interpretation of plain X-ray of chest can also raise the suspicion of the disease. Two neonates with paraesophageal hernia are reported, one with the mesenterico-axial volvulus and herniation of spleen along with the stomach, and second neonate without volvulus.

### Case Reports

#### Case 1

A one-day-old male neonate presented with minimal respiratory distress since birth. Physical examination was essentially normal except for mild tachypnea (50/min). Infantogram revealed presence of gaseous shadow in the left paravertebral region of lower chest, as well as in the subdiaphragmatic area, with presence of nasogastric tube in the subdiaphragmatic stomach (*Fig. 1*). An air contrast study for esophagus and stomach showed the presence of stomach in the lower chest on lateral infantogram. Exploratory laparotomy through left subcostal incision revealed a paraesophageal hernia.

There was no volvulus of stomach, and stomach could be reduced into the peritoneal cavity with ease. The esophageal hiatus was narrowed using interrupted Vicryl sutures, and gastropexy was added to the procedure. This baby made an uneventful recovery and is now three years old and asymptomatic.

#### Case 2

A seven-day-old neonate weighing 3 kg was referred to us with a suspected diagnosis

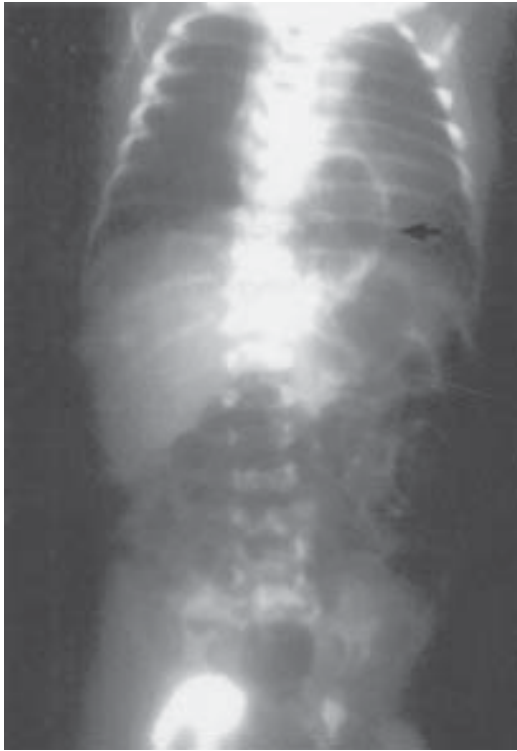

Fig 1. Infantogram (A-P view) of case 1 showing a gas filled cystic lesion (arrow) in the left lower chest.

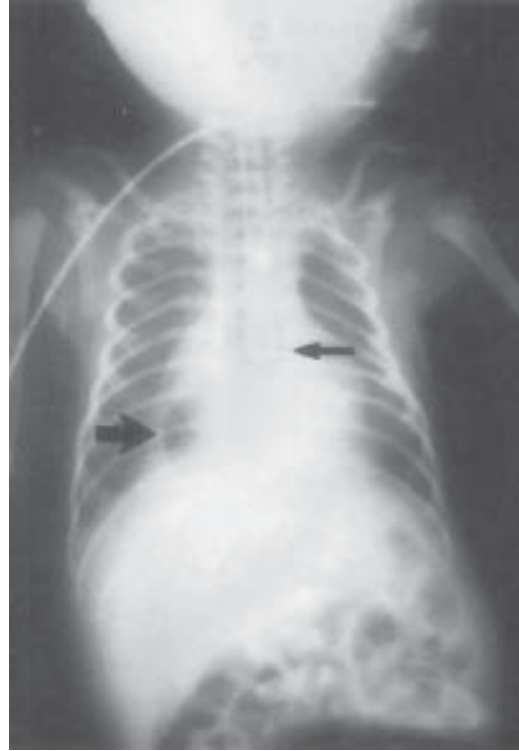


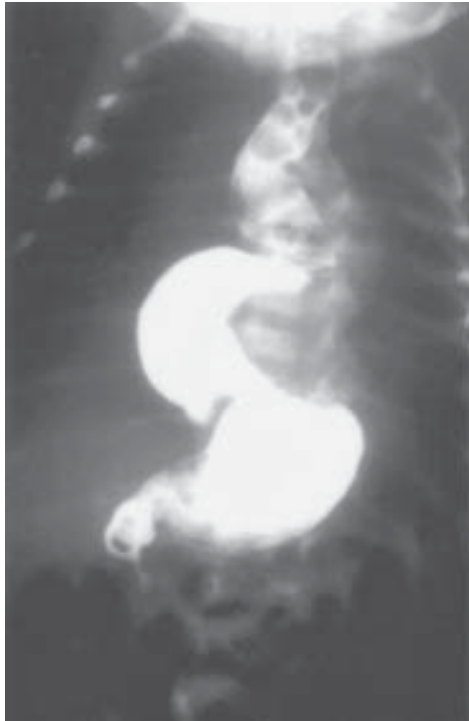
Fig 2. Infantogram of case 2 with catheter in lower esophagus at T7 vertebra level (small arrow) and intrathoracic stomach in the right lower chest (large arrow).

of esophageal atresia due to excessive salivation, regurgitation of feeds and 2 episodes of cyanotic spells. Physical examination did not reveal any overt signs, but an orogastric tube was arrested at 15 cm from the gum margin. Plain X-ray of the chest with orogastric tube *in situ* demonstrated the presence of tip of the tube at seventh thoracic vertebral level as well as the presence of an abnormal gas shadow in the right para vertebral region in the lower chest (Fig. 2). A contrast study using water-soluble contrast revealed dilatation of esophagus and an intrathoracic stomach (Fig. 3). The stomach was in a state of volvulus and a small quantity of contrast passed distally into the duodenum.

A laparotomy was performed; surprisingly the spleen was also herniated alongside the stomach. The herniated contents were reduced into the peritoneal cavity with derotation of the volvulus. The esophageal hiatus was about 3 cm in size, which was narrowed with interrupted sutures and a fundopexy performed with fixation of the gastric fundus to the left hemidiaphragm. An uneventful post-operative recovery followed and the child is doing well at one-year follow-up.

### Discussion

Paraesophageal hernia is one of the several known defects of the diaphragm. Paraesophageal hernias are seen at all ages throughout



*Fig. 3. Upper GI contrast study-showing mesenterico-axial volvulus of stomach: A small quantity of contrast passing distally into duodenum.*

life, but rarely present in the neonatal period. However, paraesophageal hernia has also been reported in siblings(3). A variety of symptoms may occur, but it is common that the symptom complex is indicative of upper alimentary tract obstruction, with or without a cyanotic episode. In patients with the associated gastric volvulus, the symptomatology may indicate an esophageal atresia(2), as was suspected in case 2 of our study. In these neonates an orogastric tube gets arrested at 14 or 15 cm from the gum margin (*Fig. 2*), a level lower than that usually seen in esophageal atresia. An upper gastrointestinal tract contrast study usually shows the presence of stomach in the lower thorax. Rarely, an infant with neonatal Marfan syndrome can present with hiatus/para

esophageal hernia with or without gastro-esophageal reflux(4).

A plain X-ray of chest in these neonates needs to be viewed carefully as the gastric shadow can be seen in lower chest, by the side of esophagus and separate from the pulmonary shadow (*Figs. 1 and 2*). In both the neonates a contrast study was performed for delineation of anatomy of esophagus and stomach, and a correct preoperative diagnosis could be made.

Case 2 was unique in that the spleen was herniated alongside the stomach into the thoracic cavity, to our best of knowledge this has not been reported earlier. Both the neonates had isolated paraesophageal hernia and are doing well 1 year and 8 months postoperatively. The purpose of this paper is to draw attention to the possibility of paraesophageal hernia in neonatal period and to suspect this disease entity even on plain x-ray of chest.

*Contributors:* DK and RS designed the study. KLNLR helped in the preparation of the manuscript.

*Funding:* None.

*Competing interests:* None stated.

#### REFERENCES

1. Anderson KD. Congenital diaphragmatic hernia. *In:* Welch KJ, Randolph JG, Ravitch MM, Rowe MC, editors. *Pediatric Surgery* 4th ed. Chicago: Year Book Medical Publishers; 1986. p. 599.
2. Yadav K, Myers NA. Paraesophageal hernia in the neonatal period-another differential diagnosis of esophageal atresia. *Pediatr Surg International* 1997; 12: 420-421.
3. Baglaj SM, Noblett HR. Paraesophageal hernia in children: familial occurrence and review of the literature. *Pediatr Surg International* 1999; 15: 85-87.
4. Parida SK, Kriss VM, Hall BD. Hiatus/paraesophageal hernias in neonatal Marfan syndrome. *Am J Med Genet* 1997; 72: 156-158.